

# Anterior cruciate ligament injury in children: update of current treatment options

Leslie S. Beasley, MD, and Steven C. Chudik, MD

As our society's interest in competitive athletics has grown, so has the participation of our youth. Unfortunately, along with this increase in participation has come a predictable increase in rate of injury. More specifically, anterior cruciate ligament injury in the skeletally immature individual is being recognized with increasing frequency and currently poses an unsolved clinical problem. Conservative management of midsubstance anterior cruciate ligament tears in the skeletally immature population has been shown to have an unfavorable prognosis related to functional knee instability, subsequent meniscal tears, and the development of early degenerative arthritis. Despite poor outcomes following conservative treatment, many orthopaedic surgeons have been reluctant to perform anterior cruciate ligament reconstructions in skeletally immature patients due to the potential for physeal injury and resultant growth disturbance. Although there is growing evidence in the literature suggesting that anterior cruciate ligament reconstruction in the adolescent population may be safely performed using anatomic, transphyseal techniques, there are insufficient data to provide concrete guidelines in treatment of anterior cruciate ligament injuries in the prepubescent population. Management of these injuries, therefore, must be based on the physiologic and skeletal maturity of the child. Anterior cruciate ligament reconstruction in the skeletally immature individual still poses a clinical problem with the safest and most effective techniques still evolving. *Curr Opin Pediatr* 2003, 15:45–52 © 2003 Lippincott Williams & Wilkins, Inc.

Hospital for Special Surgery, New York, New York, USA.

Address all correspondence to Leslie S. Beasley, MD, Hospital for Special Surgery, 535 East 70th Street, New York, NY 10021, USA; e-mail: beasleyl@hss.edu

**Current Opinion in Pediatrics** 2003, 15:45–52

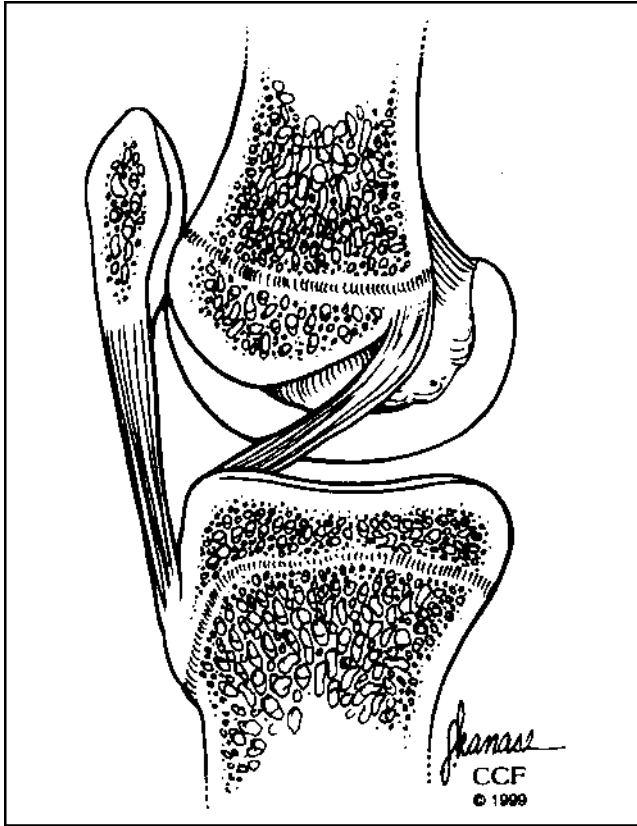
Midsubstance tears of the anterior cruciate ligament (ACL), once thought to be uncommon injuries in children and adolescents, are being reported with increasing frequency [1••,2–13]. Unfortunately, the management of these injuries in children still remains controversial. Conservative management of ACL injuries in children has been shown in several clinical studies to carry a dismal prognosis. Children are active by nature and are unable to comply with the activity modifications necessary for successful conservative management. The functional knee instability associated with their ACL insufficiency has been shown to lead to the subsequent development of meniscal tears and early degenerative arthritis [1••,6,14–16]. On the other hand, the standard techniques for ACL reconstruction require anatomic, intra-articular placement of an ACL graft through drill holes placed across both the distal femoral and proximal tibial physes. These techniques directly injure a portion of the growing physes and can potentially result in growth disturbance. Therefore, managing ACL injuries in the skeletally immature patient requires a deep respect for the unique anatomy and physiology of the growing pediatric knee, a thorough understanding of the outcome of conservative management of these injuries, and a continually evolving knowledge of the past, present, and upcoming basic science and clinical data available on surgical options for reconstruction.

## Background

### Anatomy

The normal ACL is an intra-articular but extra-synovial structure in the knee. Proximally, it originates from the posterior aspect of the medial surface of the lateral femoral condyle. Distally, the ACL inserts anterior and lateral to the anterior tibial spine (Fig. 1) [17].

Recently, Behr *et al.* [18••] used 12 fresh-frozen human fetal specimens and 13 skeletally immature knees (aged 5–15 years) to define the spatial relation of the ACL to the epiphyseal side of the distal femoral physis. They found that the femoral origin of the fetal ACL developed as a confluence of ligament fibers with periosteum at 20 weeks gestation and established a secure epiphyseal attachment by 36 weeks. They also verified that the femoral origin of the ACL remained an epiphyseal structure from fetal development through skeletal maturity and that the average distance of the ACL origin site was  $2.66 \pm 0.18$  mm distal to the femoral physis (Fig. 2). Proximity of the ACL origin to the posterolateral portion of the

**Figure 1. Native ACL in a pediatric knee**

Sagittal view of a skeletally immature knee demonstrating the proximity of the ACL origin to the distal femoral physis. Reprinted with permission from Andrich JT [2].

distal femoral physis poses significant technical difficulties with regard to reconstructing the ACL. Staying all epiphyseal is challenging as well with regard to proximity to the physis and sparse amount of epiphyseal bone available in the highly cartilaginous immature distal femur.

Shea *et al.* [19••] investigated differences in ACL anatomy between adults and children and using MR images. They concluded that although skeletally immature subjects may have smaller dimensions of the tibia and ACL, the region of the tibial attachment of the ACL is proportional in the sagittal plane to that of adult subjects. Therefore, when reconstruction of an ACL in a skeletally immature patient is performed, the smaller dimensions of the tibia need to be considered; however, anatomic landmarks can still be relied upon for graft placement.

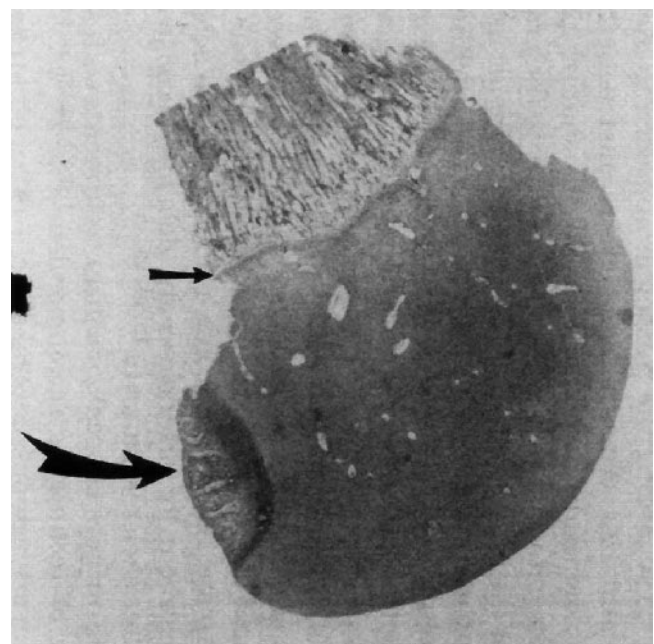
#### Physeal physiology

About 65% of the total growth of the lower limb comes from the physes about the knee; the distal femoral physis contributes about 37% and the proximal tibial physis about 28%. Therefore, if the physis is injured when the

child has a significant amount of growth remaining, there is the potential for the development of marked deformity.

A series of studies in rabbits have documented that drilling a hole measuring 7% to 9% of the cross-sectional area of the physis is sufficient to cause a growth disturbance [20–22]. Fortunately, the relative tunnel size necessary to perform ACL reconstruction in humans has been estimated to be only 3% to 4% of the cross-sectional area of the physis. Other basic science studies have shown that placement of soft-tissue graft material within a tunnel drilled across the growth plate can prevent bone formation within the tunnels and may further prevent growth disturbances even within larger holes [23]. Other studies have shown that filling the holes with threaded screws or cancellous bone graft, as would be done in adult ACL reconstruction with bone patellar tendon bone graft, will bridge the physis and could cause growth disturbance [24,25].

When performing an anatomic ACL reconstruction, the graft is typically placed in a tunnel through the center of the tibial physis, whereas on the femoral side, the tunnel is placed eccentrically across the femoral physis either through a drill hole or in the over-the-top position. Because only femoral growth abnormalities have been reported clinically [7,26,27], it appears that placing an eccentric hole or graft in the femur is more likely to affect physeal growth than drilling a central tunnel in the tibial physis. It is unclear whether this difference is due to

**Figure 2. Histologic section of the immature distal femur**

Section of the distal femur of a fetal specimen stained with hematoxylin and eosin demonstrating the distance between the ACL origin (large curved arrow) and the physal plate (small straight arrow). Reprinted with permission from Behr *et al.* [18].

factors inherent to the femoral and tibial physes or rather the location of the insult (central or eccentric). Basic science studies have shown that creating central physal injuries by drilling may not result in subsequent growth deformities, whereas creating peripheral injuries of similar size can cause significant growth deformity [28,29].

A more recent animal study has used a tensioned soft-tissue graft in conjunction with an anatomic transphysal ACL reconstruction technique to cause a physal growth disturbance [30••]. They reported that compression alone from a tensioned graft across the physis can also be detrimental to physal growth. In addition, they felt that only the eccentrically placed femoral graft asymmetrically limited femoral growth, whereas the centrally placed tibial graft did not appear to affect tibial growth.

Despite our lack of a complete understanding of the mechanisms and causative factors involved in growth disturbances, clinical and basic science data suggest that placing relatively small tunnels (7%–9% of the physal area) across the physis that are centrally located and filled with soft tissue are less likely to result in growth disturbance, whereas, the placement of larger, more eccentric tunnels filled with cancellous bone or placed under significant tension are more likely to lead to growth arrest.

## Clinical presentation and evaluation

### History and physical examination

Obtaining an accurate history and performing a thorough physical exam are much more difficult in children as compared with adults. Harvell *et al.* [10], Angel and Hall [3,14], and Kloeppel-Wirth *et al.* [31] found that when compared with arthroscopic assessment, even the best attempts at an accurate history and physical examination correlated poorly with a correct preoperative diagnosis in children with acute knee injuries. Angel and Hall [14] found that a physician had a 56% chance of making the correct diagnosis in a pediatric acute knee hemarthrosis (blood-filled joint) based on clinical grounds alone. Harvell *et al.* documented only 55% of preoperative clinical diagnoses in children with acute knee hemarthroses to be confirmed at surgery [10].

Older patients may articulate a typical history suggestive of an ACL tear. Often times they will describe a distinct “pop” heard at the time of the injury, followed by the feeling that something shifted in the knee. This is usually followed by the onset of a painful effusion and the inability to return to play. They also may be able to recall the exact mechanism of injury to the knee, which usually does not involve an impact to the knee but rather a noncontact deceleration, or changing-direction maneuver. Unfortunately, children usually cannot provide such a detailed account of the injury.

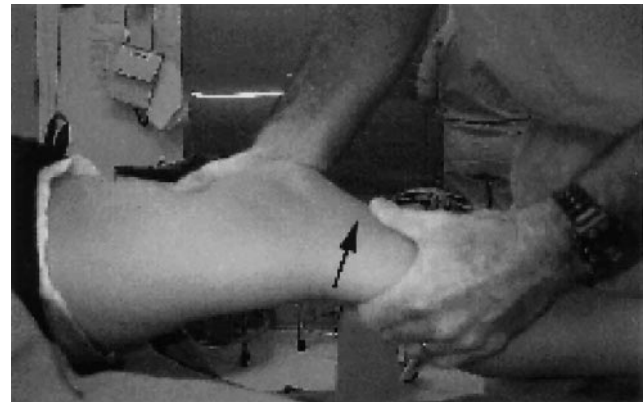For the first few weeks after the injury, the physical examination may be limited secondary to a painful effusion, resulting in the patient’s inability to cooperate with the exam. Important aspects of the knee examination include detecting an effusion, determining the range of motion, and localizing tenderness, specifically along the joint lines, the physes, or over the collateral ligaments. Laxity must be assessed in all planes and differentiated from the physiologic laxity, which can be significant in children, especially girls [4]. The contralateral knee should serve as a baseline if it has not also sustained a previous injury. Provocative maneuvers including Lachman, anterior drawer, and pivot shift testing should be performed on both knees, with close attention paid to quality of the endpoint (Fig. 3). The knee should also be tested against varus and valgus stresses. Qualitative and quantitative differences between knees should be recorded. Due to the limited reliability of the initial clinical examination, magnetic resonance imaging (MRI), exam under anesthesia, and arthroscopy can help yield a more definitive diagnosis [12].

Several studies have been done arthroscopically evaluating acute knee injuries presenting with hemarthroses in pediatric patients [10–12,14]. Anterior cruciate ligament injuries were found in up to 62% of these patients, with associated meniscal tears in up to 58%. These studies underline both the significance of a hemarthrosis in a child’s knee as well as the frequency of associated intra-articular pathology.

### Assessment of skeletal maturity

The risk for potential growth disturbance after ACL reconstruction is inversely proportional to the amount of growth remaining in a child and a standard assessment of maturity can be useful. The significance of assessing

**Figure 3. The Lachman test**



The Lachman test is the most definitive and easily performed test for ACL tears. The knee should be positioned at 20–30° of flexion. The upper hand stabilizes the distal thigh; the lower hand, with the thumb on the tibial tubercle, translates the tibia forward on the femur. Reprinted with permission from the ACL Study Group Website, [www.aclstudygroup.com](http://www.aclstudygroup.com).

skeletal maturity lies in the fact that an injury to a physis in a child who is Tanner stage 1 or 2 with wide-open physes and has 10 cm of growth left may have greater implications than an injury to a physis in a child who is Tanner stage 4 or 5 and is nearly skeletally mature with minimal growth remaining. Clinical studies have shown [1••,8,32–34••] that adult-type ACL reconstruction using either hamstring tendons or bone patellar tendon bone graft passed through both the femoral and tibial physes can be performed without a risk of growth disturbance in older children close to skeletal maturity.

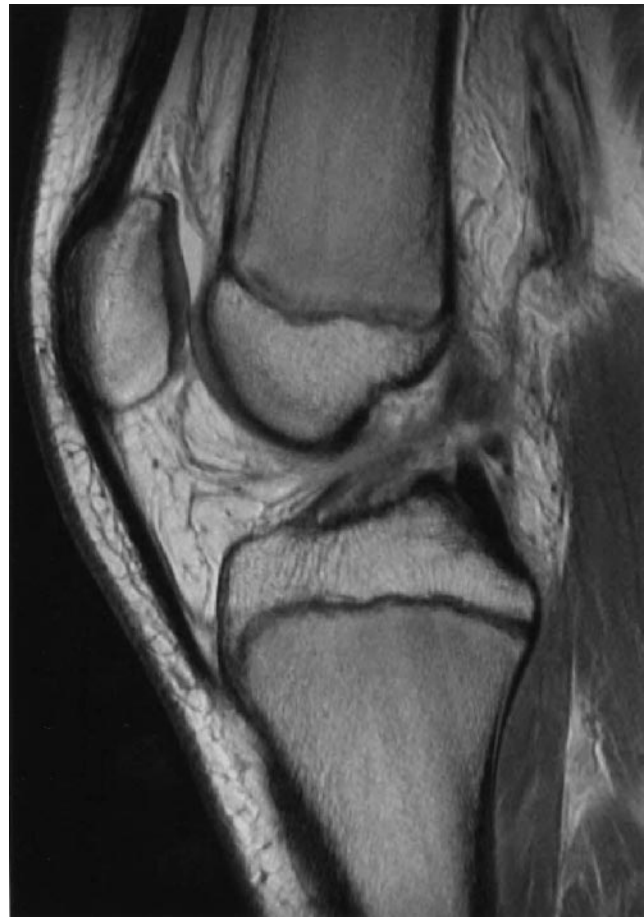In younger children, skeletal maturity is highly variable and does not always correlate with chronologic age. Determining the patient's skeletal maturity directly or indirectly by some standard means can provide the physician with some objective information to help counsel the parents about the potential risks of growth disturbance. The patient should be assessed physiologically for signs of secondary sexual characteristics such as menarche and the development of axillary and pubic hair, as described by Tanner and Davies [35]. History of recent changes in shoe size, an adolescent growth spurt, and the height of their parents or siblings can all be useful indicators of skeletal maturity. Additionally, the patient can be assessed radiographically, most often done by the evaluation of a hand and wrist x-ray for bone age.

#### Radiographic assessment

In children, as in adults, imaging of an injured knee should begin with plain radiographs. The four standard views include anteroposterior, lateral, skyline, and tunnel views. Plain x-rays can be used to assess malformation of the tibial spine or femoral notch, which can be associated with congenital absence of the cruciate ligaments, as well as to diagnose Salter-Harris fractures and tibial eminence fractures. If needed, stress views of the affected knee or comparison views of the contralateral knee can be obtained [36].

Magnetic resonance imaging is considered the gold standard in imaging ACL tears in adults, with sensitivity and specificity reported near 100% [37,38]. Its diagnostic role in children has been only slightly less predictable (Fig. 4) [39,40]. Some advantages lie in the fact that it can elucidate associated intra-articular injuries that commonly confound an ACL tear (*ie*, meniscal pathology, osteochondral lesions, and collateral ligament injuries). Unfortunately, some young children may not be able to remain still for the test, occasionally requiring sedation. Binfield and Williams [13] reported on the diagnostic accuracy for a total of 301 knee MRI scans versus arthroscopy in patients aged 16 or less. In their series, they found that MRI was a safe and accurate method of assessing the injured immature knee and patients did not usually require sedation or anesthesia. Our experience is that current high-quality MR is very accurate in diagnosing ACL

**Figure 4. MRI of an acute ACL tear in a skeletally immature knee**



Sagittal plane MRI of an acute ACL tear in a skeletally immature knee, notable for the discontinuity of the ligament in its midsubstance.

tears, similar to that in adults, and sedation is infrequently necessary. Some tertiary centers are starting to perform physal sequences to assess maturity; however, standards are still yet to be established.

#### Treatment

##### Conservative care

Several studies have documented the poor results associated with conservative treatment of ACL tears in children as well as the preponderance of associated intra-articular pathology, most often meniscal tears. Conservative treatment has typically consisted of three parts: activity modification, a rehabilitation program, and, occasionally, bracing. Activity modification specifically requires the restriction of high-level acceleration/deceleration sports that require a rapid change of direction [41]. This is very difficult to impose on children, as many of their daily activities include recreational running and playing. The rehabilitation program should aim to re-establish a normal quadriceps and hamstring ratio [42] as well as focus on range of motion, strengthening, and proprioception. Patients should have

regained at least 90% of their normal strength on Cybex testing and passed functional progression tests prior to returning to athletics. Many physicians recommend that an ACL functional brace should then be fitted and used for sporting activities [43].

Kannus and Jarvinen [6], McCarroll *et al.* [43], Angel and Hall [3], Graf *et al.* [15], Mizuta *et al.* [16], Janarv *et al.* [28], and most recently, Aichroth *et al.* [1••] have all reported on children and adolescents with ACL ruptures that were treated conservatively. Concomitant meniscal tears were found in up to 72% of these patients, with a high rate of subsequent tears over time. Nearly all patients in these studies with complete ACL tears developed functional instability, or “giving way.” These authors demonstrated that conservative treatment of this injury in this age group led to progressive instability of the knee despite activity modification, rehabilitation, and bracing. This instability led to deterioration in function, further meniscal injury, and osteochondral damage. They felt that a more aggressive approach to disruption of the ACL in the skeletally immature individual was indicated.

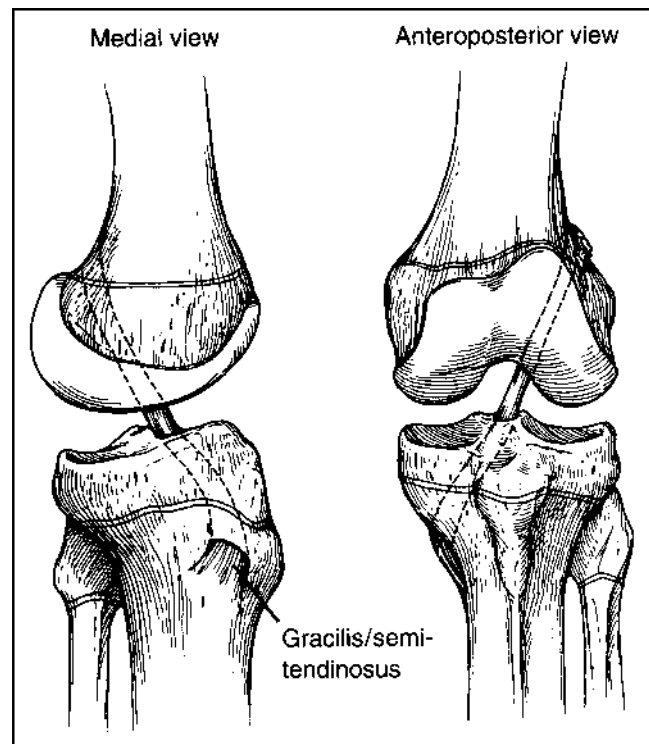
#### Operative treatment

As a result of over a decade of studies documenting poor results associated with conservative management of complete ACL tears in the skeletally immature population, there has been increased attention in recent years paid to surgical reconstruction of this ligament. However, with the concern of growth disturbance from physal violation, early techniques avoided the physes and included primary repair [4,5] of the ligament and nonanatomic reconstructions [28,44–47], both of which have failed to consistently restore stability to the knee. More current techniques attempt to restore the anatomic intra-articular position of the ACL while minimizing injury to the physes about the knee.

In the literature, a number of different surgical techniques have been reported to successfully restore stability to the knee and avoid growth disturbances [1••,7,8,27,32–34••,48]. Over-the-top and transphyseal techniques have been the most popular. The over-the-top technique involves passing a graft through a central tibial tunnel across the tibial physis, then up through the femoral notch and around the posterior aspect of the lateral femoral condyle. The graft is then fixed to the lateral aspect of the distal femoral metaphysis, thus crossing but not directly violating the femoral physis (Fig. 5). Transphyseal reconstructions are the most anatomic and isometric and mimic the technique used in adults. In this procedure, the graft is passed through drill holes across both the distal femoral and proximal tibial physes (Figure 6).

Despite reports of clinical success using these techniques, most of these studies provide short-term follow-

**Figure 5. Over-the-top ACL reconstruction**



Partial transphyseal ACL reconstruction in which a central patellar or hamstring tendon graft is passed through a tunnel across the tibial physis and in the over the top femoral position. (Reprinted with permission from Stanitski CL [36].)

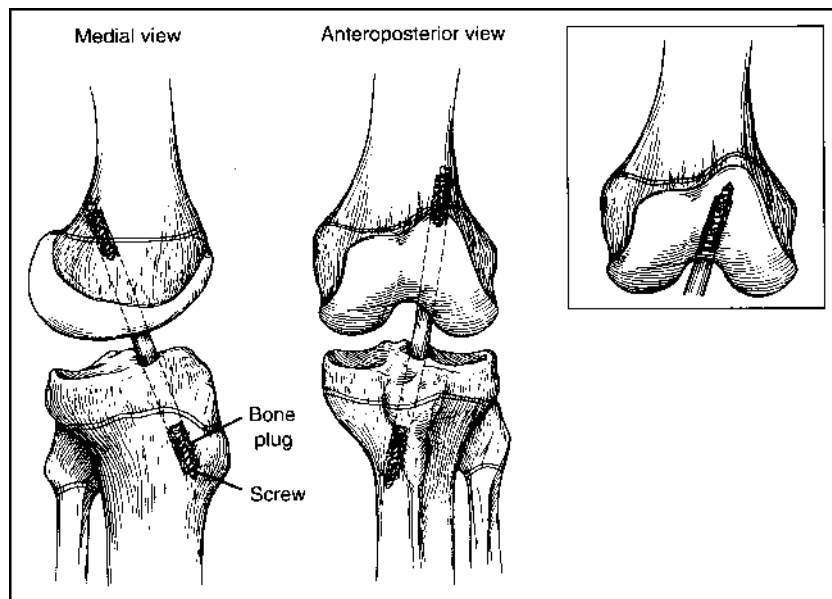
up and fail to document the skeletal maturity of their subjects using a standardized method. Thus, it is difficult to extrapolate their results to other patients and make any concrete recommendations about the safety, timing, and long-term outcome of these techniques.

#### Growth disturbances

Although there has been great fear of growth disturbance following ACL reconstructions in children with open physes, there are few documented reports in the literature. Furthermore, most reports of growth disturbance have been attributable to errors in surgical technique. Surgical errors have included inadvertent hardware fixation across the physis, bone grafting across the physis with the bone plugs of a bone patellar tendon bone graft, and excessively large tunnels [49••]. There are two other reported growth disturbances that occurred in patients who underwent a “no-longer-in-use” nonanatomic lateral extra-articular tenodesis. From the report, it is unclear whether technical error or an asymmetric tenodesis across the distal femoral physis was at fault for the alteration in growth.

#### Future directions

Recently, Anderson [50••] presented the results of a novel technique for ACL reconstruction used in a group of young patients. Twelve patients, average age 13, un-

**Figure 6. Transphyseal ACL reconstruction**

Complete transphyseal ACL reconstruction in which a patellar tendon graft is placed through tibial and femoral tunnels. Reprinted with permission from Stanitski CL [36].

derwent anatomic, physeal-sparing ACL reconstruction using quadruple hamstring grafts. They were followed for an average of 4.2 years. He reported good subjective and objective outcomes with no significant limb-length inequality. The average growth of patients in this group was 16.3 cm, confirming that they were skeletally immature at the time of surgery. He concluded that this was a safe and effective technique for preadolescent patients.

To date, there have been few prospective studies to compare reconstructive techniques in which the physiologic and skeletal maturity of patients undergoing ACL reconstructions has been adequately documented. Information presented at the 2002 ACL Study Group Meeting by Paletta marks the first of such studies [51••]. Paletta presented a comparison of ACL reconstruction techniques in skeletally immature patients using hamstring autograft tendons. Fourteen children, aged 10 to 13, were reconstructed. All males were Tanner stage 1, 2, or 3 with skeletal age <13, and all females were premenarchal with skeletal age <14. In all reconstructions, the tibial tunnel was transphyseal. In 6 of 14, the femoral limb was placed in the over-the-top position, and in the remaining 8, it was placed through a transphyseal femoral tunnel. At a minimum follow-up of 2 years, no patients demonstrated significant leg length discrepancies or angular deformities. Objective measurements of stability were superior in the transphyseal femoral tunnel group; however, subjectively and in regards to level of return-to-sports activity, both the techniques yielded good results. Both techniques were demonstrated to be safe in this skeletally immature age group.

With the increasing number of skeletally immature children sustaining ACL tears, and the basic science and

clinical experiences we have to date, there will need to be further studies to clearly delineate the safest and most efficacious management of these injuries in the prepubescent child.

### Conclusions and current recommendations

The literature has convincingly demonstrated poor outcomes following conservative treatment of ACL injuries in the active skeletally immature patient related to the development of functional instability, subsequent meniscal tears, and degenerative arthritis. There still exists substantial controversy and practice variation with regard to management of ACL injuries in skeletally immature patients. The treatment of midsubstance ACL injuries in the pediatric population should depend on the physiologic and skeletal maturity of the child. There is growing evidence in the literature suggesting that ACL reconstruction in the adolescent population may be safely performed with anatomic, transphyseal techniques, using even bone patellar tendon bone graft crossing the physis. Unfortunately, there is insufficient data available to provide concrete guidelines in treatment of ACL injuries in the prepubescent population. Most authors would attempt conservative management with close follow-up of these injuries initially. If the child continues to have episodes of instability associated with the ACL insufficiency, surgical reconstruction should be performed before irreversible damage occurs to the knee. The safest and most effective technique for reconstruction is still evolving, and hopefully a combination of well-organized basic science and clinical studies can provide the answer.

### Acknowledgments

Thanks to Daniel W. Green, MD, for help with editing.

## References and recommended reading

Papers of particular interest, published within the annual period of review, have been highlighted as:

- Of special interest
- Of outstanding interest

- 1 Aichroth PM, Patel DV, Zorrilla P: The natural history and treatment of rupture of the anterior cruciate ligament in children and adolescents. A prospective review. *J Bone Joint Surg Br* 2002, 84:38–41.  
This is a prospective review of 60 children and adolescents with ACL tears; 23 were treated conservatively, which resulted in severe instability and poor knee function. Forty-seven children subsequently underwent ACL reconstruction with a transphyseal technique. None of these children suffered leg-length discrepancies, and overall results were satisfactory in 77%.
- 2 Andrich JT: Anterior cruciate ligament injuries in the skeletally immature patient. *Am J Orthop* 2001, 30:103–110.
- 3 Angel KR, Hall DJ: Anterior cruciate ligament injury in children and adolescents. *Arthroscopy* 1989, 5:197–200.
- 4 DeLee JC, Curtis R: Anterior cruciate ligament insufficiency in children. *Clin Orthop* 1983, 112–118.
- 5 Engebretsen L, Svenningsen S, Benum P: Poor results of anterior cruciate ligament repair in adolescence. *Acta Orthop Scand* 1988, 59:684–686.
- 6 Kannus P, Jarvinen M: Knee ligament injuries in adolescents. Eight-year follow-up of conservative management. *J Bone Joint Surg Br* 1988, 70:772–776.
- 7 Lipscomb AB, Anderson AF: Tears of the anterior cruciate ligament in adolescents. *J Bone Joint Surg Am* 1986, 68:19–28.
- 8 McCarroll JR, Shelbourne KD, Porter DA, et al.: Patellar tendon graft reconstruction for midsubstance anterior cruciate ligament rupture in junior high school athletes. An algorithm for management. *Am J Sports Med* 1994, 22:478–484.
- 9 Skak SV, Jensen TT, Poulsen TD, et al.: Epidemiology of knee injuries in children. *Acta Orthop Scand* 1987, 58:78–81.
- 10 Harvell JC Jr, Fu FH, Stanitski CL: Diagnostic arthroscopy of the knee in children and adolescents. *Orthopedics* 1989, 12:1555–1560.
- 11 Butler JC, Andrews JR: The role of arthroscopic surgery in the evaluation of acute traumatic hemarthrosis of the knee. *Clin Orthop* 1988, 150–152.
- 12 Stanitski CL, Harvell JC, Fu F: Observations on acute knee hemarthrosis in children and adolescents. *J Pediatr Orthop* 1993, 13:506–510.
- 13 Binfield PM, Williams LA: Magnetic resonance imaging and arthroscopy of the immature knee. *J Bone and Joint Surgery Br* 1997, 79B:233.
- 14 Angel KR, Hall DJ: The role of arthroscopy in children and adolescents. *Arthroscopy* 1989, 5:192–196.
- 15 Graf BK, Lange RH, Fujisaki CK, et al.: Anterior cruciate ligament tears in skeletally immature patients: meniscal pathology at presentation and after attempted conservative treatment. *Arthroscopy* 1992, 8:229–233.
- 16 Mizuta H, Kubota K, Shiraiishi M, et al.: The conservative treatment of complete tears of the anterior cruciate ligament in skeletally immature patients. *J Bone Joint Surg Br* 1995, 77:890–894.
- 17 Dodds JA, Arnoczky SP: Anatomy of the anterior cruciate ligament: a blueprint for repair and reconstruction. *Arthroscopy* 1994, 10:132–139.
- 18 Behr CT, Potter HG, Paletta GA Jr: The relation of the femoral origin of the anterior cruciate ligament and the distal femoral physeal plate in the skeletally immature knee. An anatomic study. *Am J Sports Med* 2001, 29:781–787.  
These authors defined the anatomic relation of the femoral origin of the ACL to the distal femoral physis in the skeletally immature knee. They demonstrated that the ACL is an all-epiphyseal structure and that there is no significant change in the distance from the physis to the ACL origin in specimens from birth to adolescence.
- 19 Shea KG, Apel PJ, Pfeiffer RP, et al.: The tibial attachment of the anterior cruciate ligament in children and adolescents: analysis of magnetic resonance imaging. *Knee Surg Sports Traumatol Arthrosc* 2002, 10:102–108.  
This study used MRI to compare the anatomy of the ACL in skeletally immature and adult subjects. They found that anatomic landmarks for the ACL were proportional in both age groups.
- 20 Janav PM, Wikstrom B, Hirsch G: The influence of transphyseal drilling and tendon grafting on bone growth: an experimental study in the rabbit. *J Pediatr Orthop* 1998, 18:149–154.
- 21 Makela EA, Vainionpaa S, Vihtonen K, et al.: The effect of trauma to the lower femoral epiphyseal plate. An experimental study in rabbits. *J Bone Joint Surg Br* 1988, 70:187–191.
- 22 Guzzanti V, Falciglia F, Gigante A, et al.: The effect of intra-articular ACL reconstruction on the growth plates of rabbits. *J Bone Joint Surg Br* 1994, 76:960–963.
- 23 Stadelmaier DM, Arnoczky SP, Dodds J, et al.: The effect of drilling and soft tissue grafting across open growth plates. A histologic study. *Am J Sports Med* 1995, 23:431–435.
- 24 Campbell CJ, Grisolia A, Zanconato G: The effects produced in the cartilaginous epiphyseal plate of immature dogs by experimental surgical traumata. *J Bone Joint Surg Am* 1959, 41:1221–1242.
- 25 Phemister DB: Operative arrestment of the longitudinal growth of bones in the treatment of deformities. *J Bone Joint Surg* 1933, 15:1–15.
- 26 Koman JD, Sanders JO: Valgus deformity after reconstruction of the anterior cruciate ligament in a skeletally immature patient. A case report. *J Bone Joint Surg Am* 1999, 81:711–715.
- 27 Andrews M, Noyes FR, Barber-Westin SD: Anterior cruciate ligament allograft reconstruction in the skeletally immature athlete. *Am J Sports Med* 1994, 22:48–54.
- 28 Janav PM, Nystrom A, Werner S, et al.: Anterior cruciate ligament injuries in skeletally immature patients. *J Pediatr Orthop* 1996, 16:673–677.
- 29 Siffert RS: The effect of staples and longitudinal wires on epiphyseal growth. An experimental study. *J Bone Joint Surg Am* 1956, 38:1077–1088.
- 30 Edwards TB, Greene CC, Baratta RV, et al.: The effect of placing a tensioned graft across open growth plates. A gross and histologic analysis. *J Bone Joint Surg Am* 2001, 83A:725–734.  
This study evaluated the effects of a tensioned connective-tissue graft placed across the skeletally immature canine physis. They reported significant angular deformities in the treated limbs and warned against excessively tensioned transphyseal ACL reconstruction in the skeletally immature population.
- 31 Kloeppel-Wirth S, Koltai JL, Dittmer H: Significance of arthroscopy in children with knee joint injuries. *Eur J Pediatr Surg* 1992, 2:169–172.
- 32 Pressman AE, Letts RM, Jarvis JG: Anterior cruciate ligament tears in children: an analysis of operative versus nonoperative treatment. *J Pediatr Orthop* 1997, 17:505–511.
- 33 Aronowitz ER, Ganley TJ, Goode JR, et al.: Anterior cruciate ligament reconstruction in adolescents with open physes. *Am J Sports Med* 2000, 28:168–175.
- 34 Edwards PH, Grana WA: Anterior cruciate ligament reconstruction in the immature athlete: long-term results of intra-articular reconstruction. *Am J Knee Surg* 2001, 14:232–237.  
This group performed 21 transphyseal ACL reconstructions in children, average age 13.7 years. At follow-up, an average of 34 months later, no limb-length discrepancies or angular deformities were noted. They concluded that ACL reconstruction through bone tunnels successfully eliminated knee instability.
- 35 Tanner JM, Davies PS: Clinical longitudinal standards for height and height velocity for North American children. *J Pediatr* 1985, 107:317–329.
- 36 Stanitski CL: Anterior cruciate ligament injury in the skeletally immature patient: diagnosis and treatment. *J Am Acad Orthop Surg* 1995, 3:146–158.
- 37 Fitzgerald SW, Remer EM, Friedman H, et al.: MR evaluation of the anterior cruciate ligament: value of supplementing sagittal images with coronal and axial images. *AJR Am J Roentgenol* 1993, 160:1233–1237.
- 38 Twaddle BC, Hunter JC, Chapman JR, et al.: MRI in acute knee dislocation. A prospective study of clinical, MRI, and surgical findings. *J Bone Joint Surg Br* 1996, 78:573–579.
- 39 Kocher MS, DiCanzio J, Zurakowski D, et al.: Diagnostic performance of clinical examination and selective magnetic resonance imaging in the evaluation of intraarticular knee disorders in children and adolescents. *Am J Sports Med* 2001, 29:292–296.
- 40 Lee K, Siegel MJ, Lau DM, et al.: Anterior cruciate ligament tears: MR imaging-based diagnosis in a pediatric population. *Radiology* 1999, 213:697–704.
- 41 Stanitski CL: Conservative treatment of complete ACL tears. *J Bone and Joint Surg Br* 1996, 78B:681.
- 42 Callaghan MJ: Conservative treatment of complete ACL tears. *J Bone Joint Surg Br* 1996, 78:680–681.
- 43 McCarroll JR, Rettig AC, Shelbourne KD: Anterior cruciate ligament injuries in the young athlete with open physes. *Am J Sports Med* 1988, 16:44–47.
- 44 Kim SH, Ha KI, Ahn JH, et al.: Anterior cruciate ligament reconstruction in the young patient without violation of the epiphyseal plate. *Arthroscopy* 1999, 15:792–795.
- 45 Micheli LJ, Rask B, Gerberg L: Anterior cruciate ligament reconstruction in patients who are prepubescent. *Clin Orthop* 1999, 40–47.

- 46 Parker AW, Drez D Jr, Cooper JL: Anterior cruciate ligament injuries in patients with open physes. *Am J Sports Med* 1994, 22:44–47.
- 47 Brief LP: Anterior cruciate ligament reconstruction without drill holes. *Arthroscopy* 1991, 7:350–357.
- 48 Lo IK, Kirkley A, Fowler PJ, et al.: The outcome of operatively treated anterior cruciate ligament disruptions in the skeletally immature child. *Arthroscopy* 1997, 13:627–634.
- 49 Kocher MS, Saxon HS, Hovis WD, et al.: Management and complications of anterior cruciate ligament injuries in skeletally immature patients: survey of the Herodicus Society and The ACL Study Group. *J Pediatr Orthop* 2002, 22:452–457.

Management and complications of pediatric ACL injuries was studied by surveying the members of the Herodicus Society and the ACL Study Group. They noted a wide practice variation in terms of management and that significant growth disturbances are rare. They recommend a guarded approach to ACL reconstruction in the skeletally immature patient with careful attention to technique.

- 50 Anderson AF: Anatomic, physeal sparing anterior cruciate ligament reconstruction in skeletally immature patients using quadruple hamstring grafts. In: ACL Study Group Meeting. Boseman, MT: 2002.

Anderson presented 4.2 years follow-up of 12 patients, average age 13, who underwent anatomic, physeal-sparing ACL reconstruction. He reported good subjective and objective outcomes with no significant limb-length inequality. He concluded that this was a safe and effective technique for preadolescent patients.

- 51 Paletta GA: ACL reconstruction in the skeletally immature athlete: comparison of two techniques. In: ACL Study Group Meeting. Boseman, MT: 2002.

Paletta presented a comparison of ACL reconstruction techniques in 14 skeletally immature patients, aged 10–13 years. In all patients, the tibial tunnel was transphyseal, whereas in 6 of 14, the femoral limb was placed over-the-top, and in the remaining 8, it was transphyseal. At 2 years follow-up, no patients demonstrated significant leg-length discrepancies or angular deformities. Objective measurements of stability were superior in the transphyseal femoral tunnel group; however, subjectively and in regards to level of return to play, both yielded good results and were demonstrated to be safe in this skeletally immature age group.