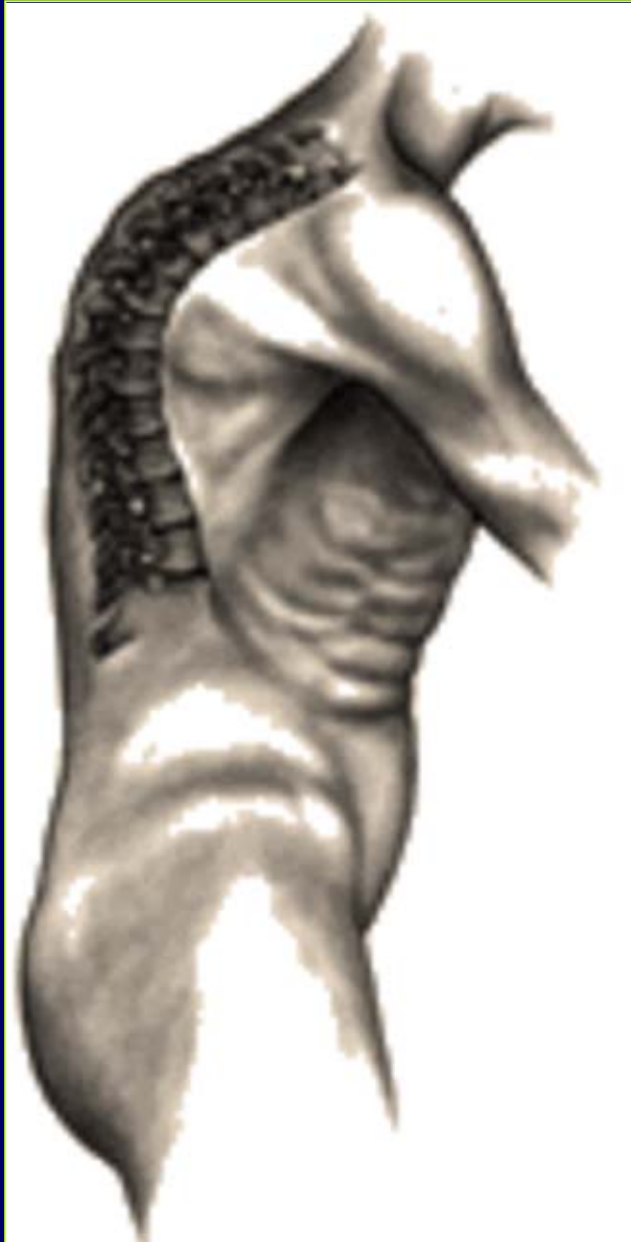



Kyphosis

Robert S. Pashman, MD

Director, Scoliosis and Spinal Deformity
Cedars Sinai Institute for Spinal Disorders

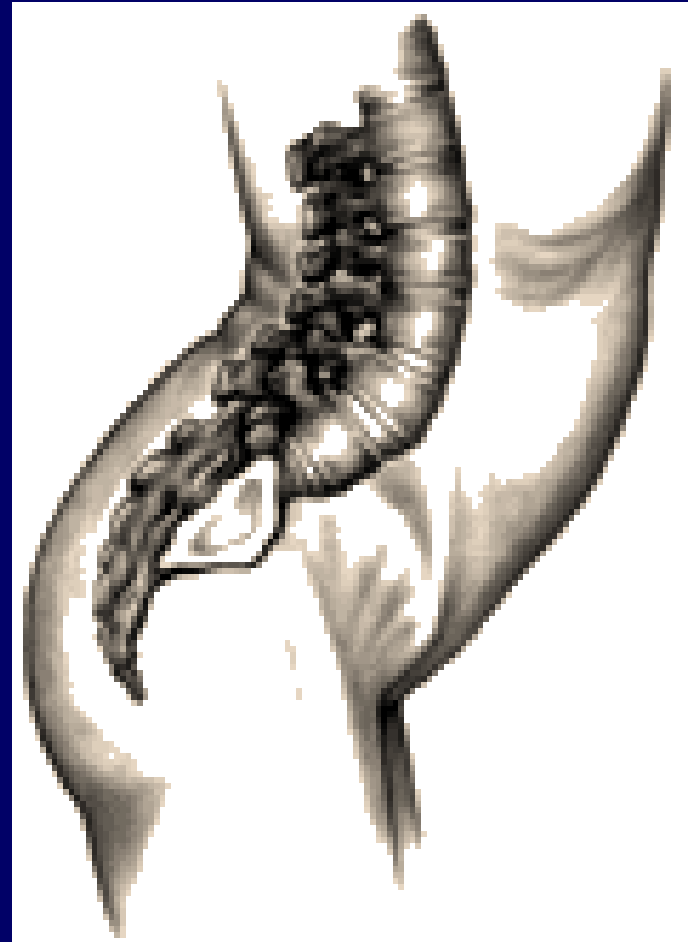Kyphosis Defined

This drawing depicts the spinal condition of kyphosis. Kyphosis is an abnormal increase in normal kyphotic (posterior) curvature of the thoracic spine which can result in a noticeable round back deformity.



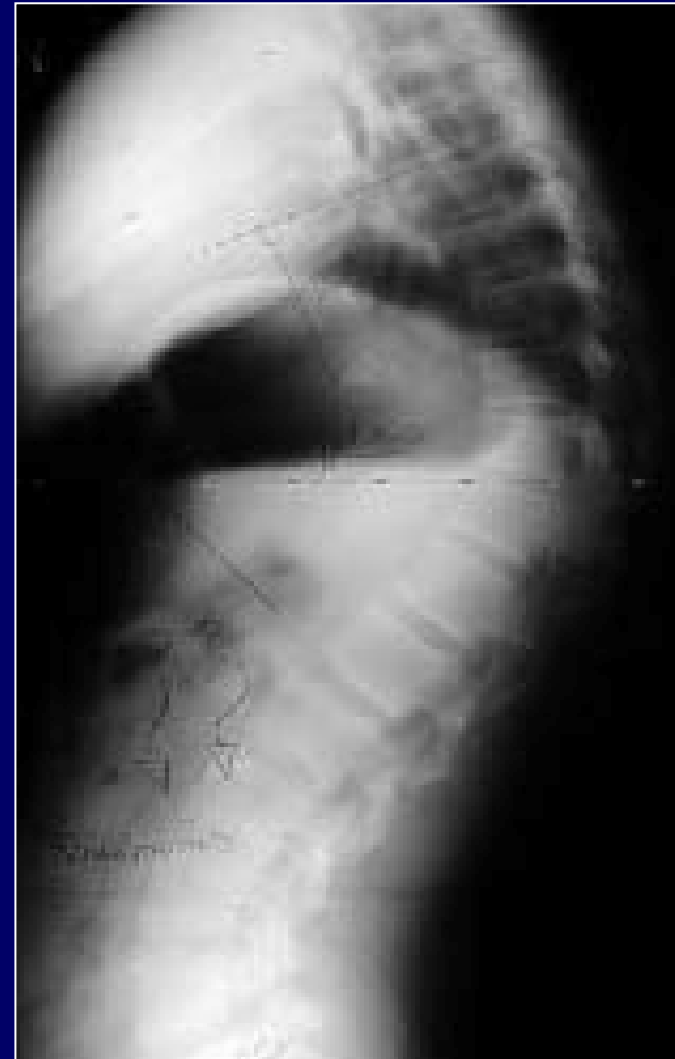Lordosis Defined

This drawing represents the spinal condition of lordosis. Lordosis is the abnormal increase in normal lordotic (anterior) curvature of the lumbar spine. This can lead to a noticeable "sway-back" appearance.



Adult Kyphosis

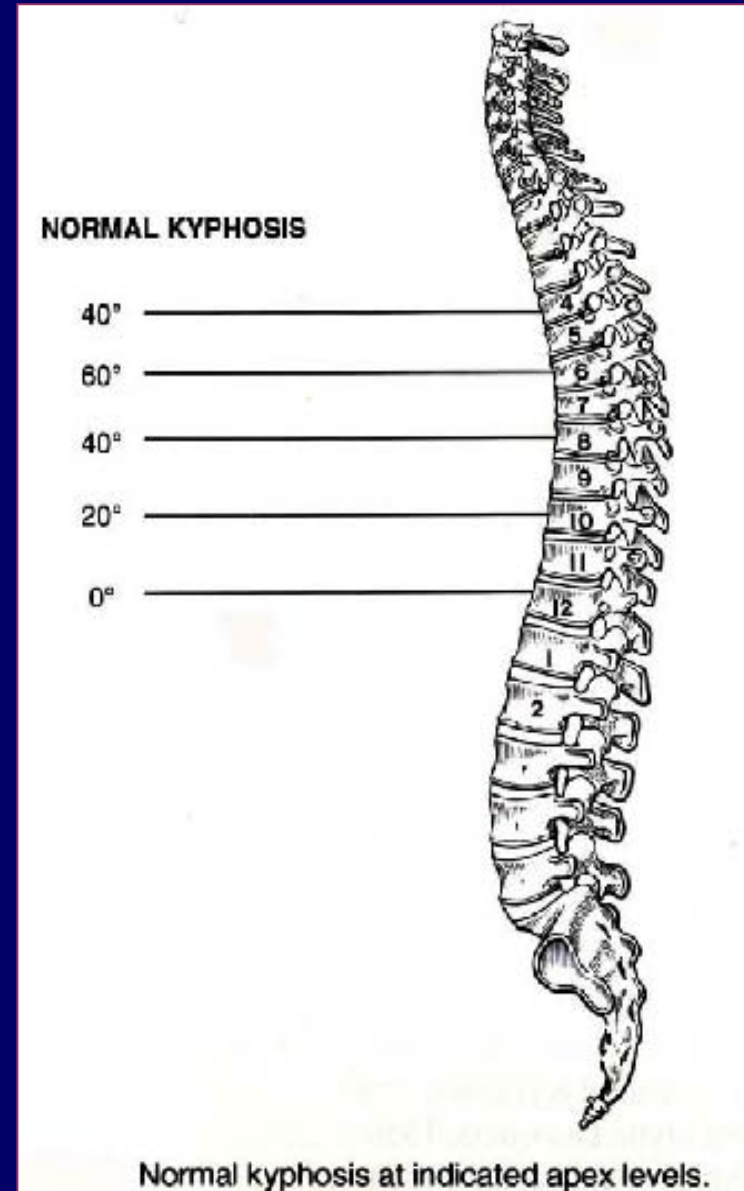
- Includes congenital/developmental causes and traumatic and iatrogenic conditions but overall osteoporosis is the most common cause of sagittal deformity
- Treatment has undergone marked evolution from the historic treatment with body casts to posterior fusion with Harrington instrumentation.
- Anterior/Posterior fusion and segmental instrumentation now can produce improved correction.



Adult Kyphosis

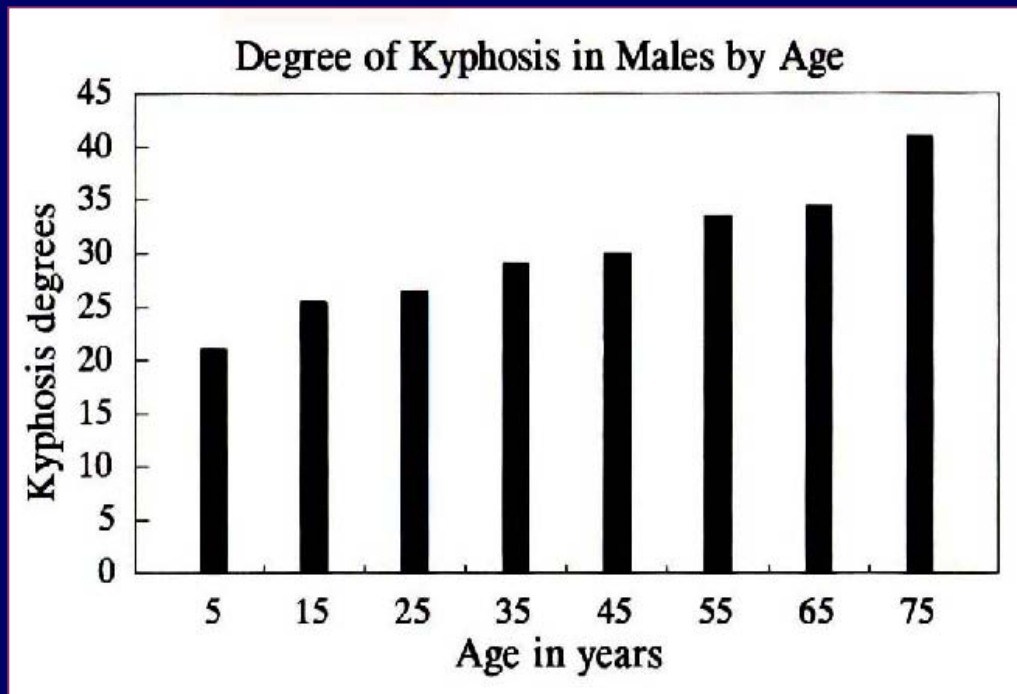
NORMAL SAGITTAL CONTOUR

- Posterior thoracic convexity is normally 20° to 40°
- An increase in thoracic kyphosis and a decrease in lumbar lordosis occur with advancing age and are thought to be more pronounced in females
- Subjects with greater lumbar lordosis generally had greater thoracic kyphosis and vice versa
- Normal lumbar lordosis in children was approximately 18 to 50 and in adults 9° to 57°



Effects of Aging on Sagittal Contour

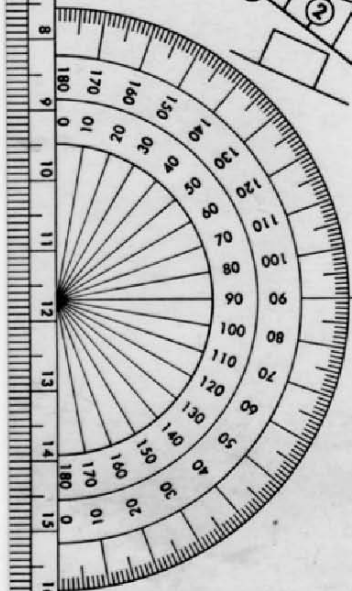
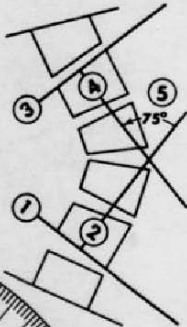
- Newborn has a slight posterior convexity from occiput to sacrum
- As the infant begins raising its head, a cervical lordosis develops
- When walking begins, the pelvis tilts, lumbar lordosis occurs and thoracic kyphosis becomes more pronounced
- The thoracic and sacral kyphosis are primary curves because they were present at birth. The cervical and lumbar lordosis are secondary curves



SCOLIOSIS MEASUREMENT OF CURVE

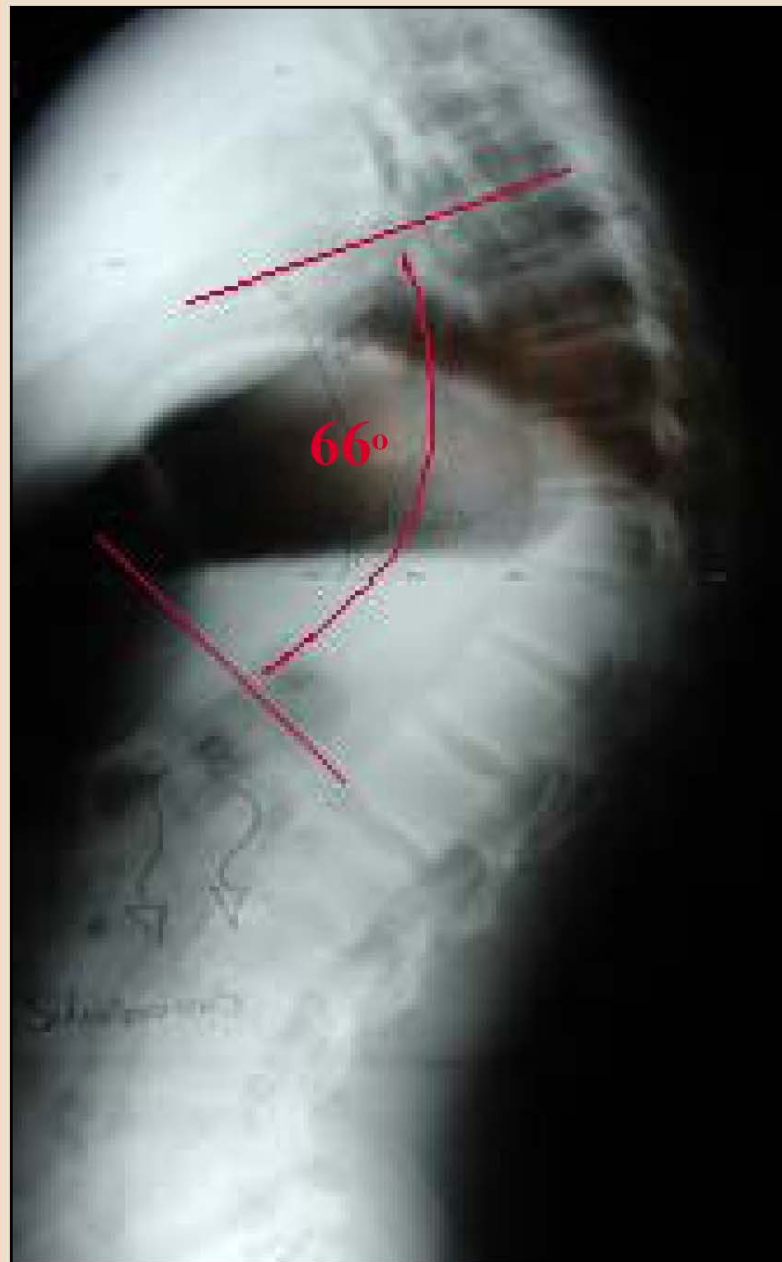J. R. COBB, M.D.

- 1 BOTTOM VERTEBRA:
LOWEST ONE WHOSE BOTTOM TILTS
TO CONCAVITY OF CURVE.
- 2 ERECT PERPENDICULAR FROM
BOTTOM OF BOTTOM VERTEBRA.
- 3 TOP VERTEBRA:
HIGHEST ONE WHOSE TOP TILTS
TO CONCAVITY OF CURVE.
- 4 DROP PERPENDICULAR FROM
TOP OF TOP VERTEBRA.
- 5 MEASURE INTERSECTING ANGLE.



USMC

United States Manufacturing Company
180 North San Gabriel Boulevard
Pasadena, California 91107 U.S.A.



Measurement of Cobb Angle is measured to determine the maximum curve angle. The measurement is from endplates of vertebrae. At the distal ends of the curve

Classifications of Kyphosis

1. Postural
2. Scheuermann's
3. Congenital
4. Neuromuscular
5. Myelomeningocele
6. Traumatic
7. Post-surgical
8. Post-irradiation
9. Metabolic
10. Skeletal dysplasias
11. Collagen disease
12. Tumor
13. Inflammatory

Some of the more common types of Kyphosis will be discussed in this presentation.

Classifications of Kyphosis - Postural

1. Postural
2. Scheuermann's
3. Congenital
4. Neuromuscular
5. Myelomeningocele
6. Traumatic
7. Post-surgical
8. Post-irradiation
9. Metabolic
10. Skeletal dysplasias
11. Collagen disease
12. Tumor
13. Inflammatory

Classifications of Kyphosis – Scheuermann's

Etiology:

- Poor posture, slouching
- Most common in adolescents and young adults
- Developing adolescent females are prone to this disorder. They will slouch and exhibit poor posture to hide their developing breasts.
- An increase in thoracic kyphosis, generally less than 60°. It is always a flexible curve.
- Compensatory hyperlordosis of the lumbar spine.
- The kyphosis corrects when the patient is asked to “stand up tall”

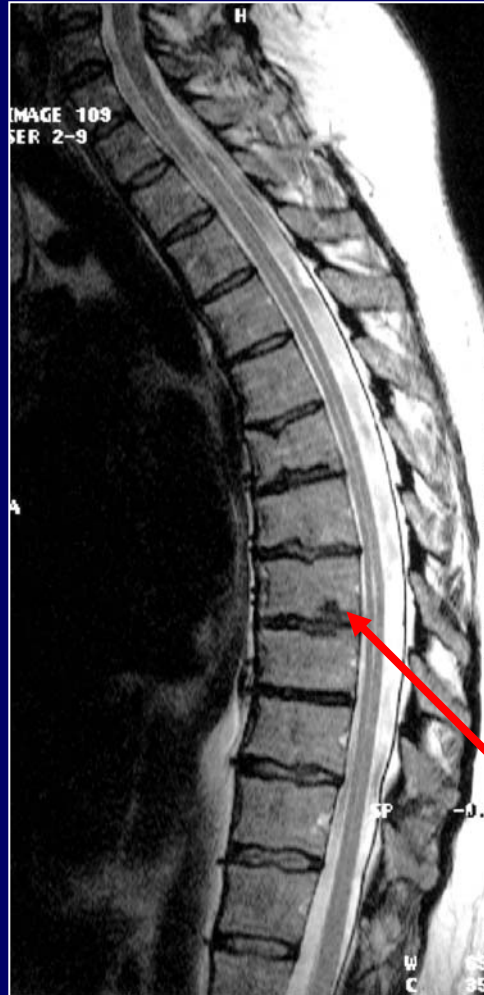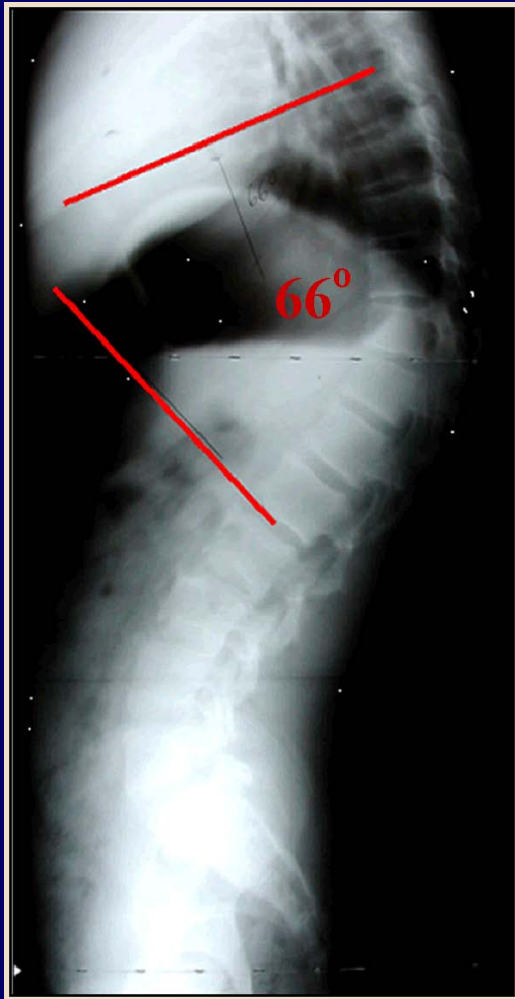Treatment

- No evidence that bracing or exercise will change the natural progression of the curvature.
- Patient education about posture is vital part of treatment.
- Parent education is also important. Nagging the child does not help.
- Surgical treatment is rarely indicated.

Classifications of Kyphosis – Scheuermann's

1. Postural
2. Scheuermann's
3. Congenital
4. Neuromuscular
5. Myelomeningocele
6. Traumatic
7. Post-surgical
8. Post-irradiation
9. Metabolic
10. Skeletal dysplasias
11. Collagen disease
12. Tumor
13. Inflammatory

Scheuermann's Kyphosis Defined



- A thoracic kyphosis of more than 40°
- Three or more adjacent vertebra that are wedged 5°
- Characterized by Schmorl's nodes, irregular endplates, and a narrowing of vertebral disc space.
- Increased vertebral anterior/posterior diameter at the apex

Schmorl's nodes

Scheuermann's Kyphosis - Demographics

- Demographics
- Prevalence varies between 1% and 8%, but only 1% seek treatment
- Age of onset is unknown
- Rarely seen before 10 or 11 years of age
- Cosmetic deformity is the most common complaint
- About 50% of those who seek medical attention have pain, but more than 78% of patients have pain if lumbar spine is involved.
- Some patients develop lumbar spondylolysis pars fracture later.

Scheuermann's Kyphosis - Etiology

Theoretical Etiology's

- Scheuermann postulated that the deformity was caused by a vascular necrosis of the vertebral ring apophysis
- Ippolito and Ponsetti have demonstrated abnormal cartilage matrix with diminished glycoproteins and a different type of collagen in affected vertebral end-plates
- Endocrinopathy has also been investigated as a possible cause
- Other authors have suggested stress injuries to the vertebral growth plates and the thoracolumbar and lumbar spine
- A genetic predisposition to Scheuermann's disease has been suggested but not proven
- Collagen weakness and stunted ossification of the vertebral endplate are characteristic.
- Osteopenia, nutrition and endocrine: these may be causative factors of increased incidence in patients with Turner's syndrome, nontropical sprue, and cystic fibrosis

Scheuermann's Kyphosis – Clinical Findings

Clinical Findings

- An adult presenting with low back pain or a teenager with poor posture with or without pain
- Physical examination usually reveals a sharp, rigid kyphosis
- Kyphosis is increased with flexion and incompletely corrected with extension
- Lumbar hyperlordosis, increased pelvic tilt and associated hamstring tightness
- Sagittal plumb line should cross C7-T1, T12-L1, and posterior sacrum normally.
- Normal thoracic kyphosis :
30°-40°, mean = 34°
- Normal lumbar lordosis : 55°-65°(two-thirds of lordosis at L4-L5 and L5-S1)
- Lumbar lordosis should be about 30° greater than thoracic kyphosis
- 30% have associated mild scoliosis.

Scheuermann's Kyphosis-Biomechanics

- Anterior column fails, resulting in compression, and posterior column fails, resulting in tension.
- Posterior structures: lamina and ligamentum flavum are relatively stronger than facets, capsules and interspinous ligaments, resisting tension.
- Growth centers adjacent to the vertebral endplate (not ring apophysis) : anterior cartilaginous columns on axial loading have stunted growth and posterior physis hypertrophy due to tension load.
- With kyphotic deformity, spinal flexors become stronger than extensor because of moment arm of kyphotic deformity.
- Deformity increases momentum and further deformity results.
- Eccentric loading affects cartilaginous growth (compression decreases growth anteriorly and tension increases growth posteriorly, resulting in more kyphosis).

Scheuermann's Kyphosis – Bracing

- Brace is used for vertebral wedging greater than 5° and curves between 45° - 65° , in patients with 1 to 2 years of growth remaining.
- Milwaukee brace for apex above T9
- TLSO for apex below T9 and thoracolumbar curves
- Curve correction and wedging improvement of about 40% can be expected after 6 to 12 months. The brace should be weaned with skeletal maturity, but loss of correction is expected after 10 years.
- The brace may have to be changed every 4-6 months until maximum correction is achieved.
- Exercise stressing pelvic tilt, abdominal strengthening, spinal flexibility, and extension of the thoracic spine is an important part of the treatment plan.

Scheuermann's Kyphosis – Treatment options

NON-OPERATIVE TREATMENT

- Brace treatment is controversial
- Although some loss of correction occurred over time, final results showed improvement in 69% of the patients

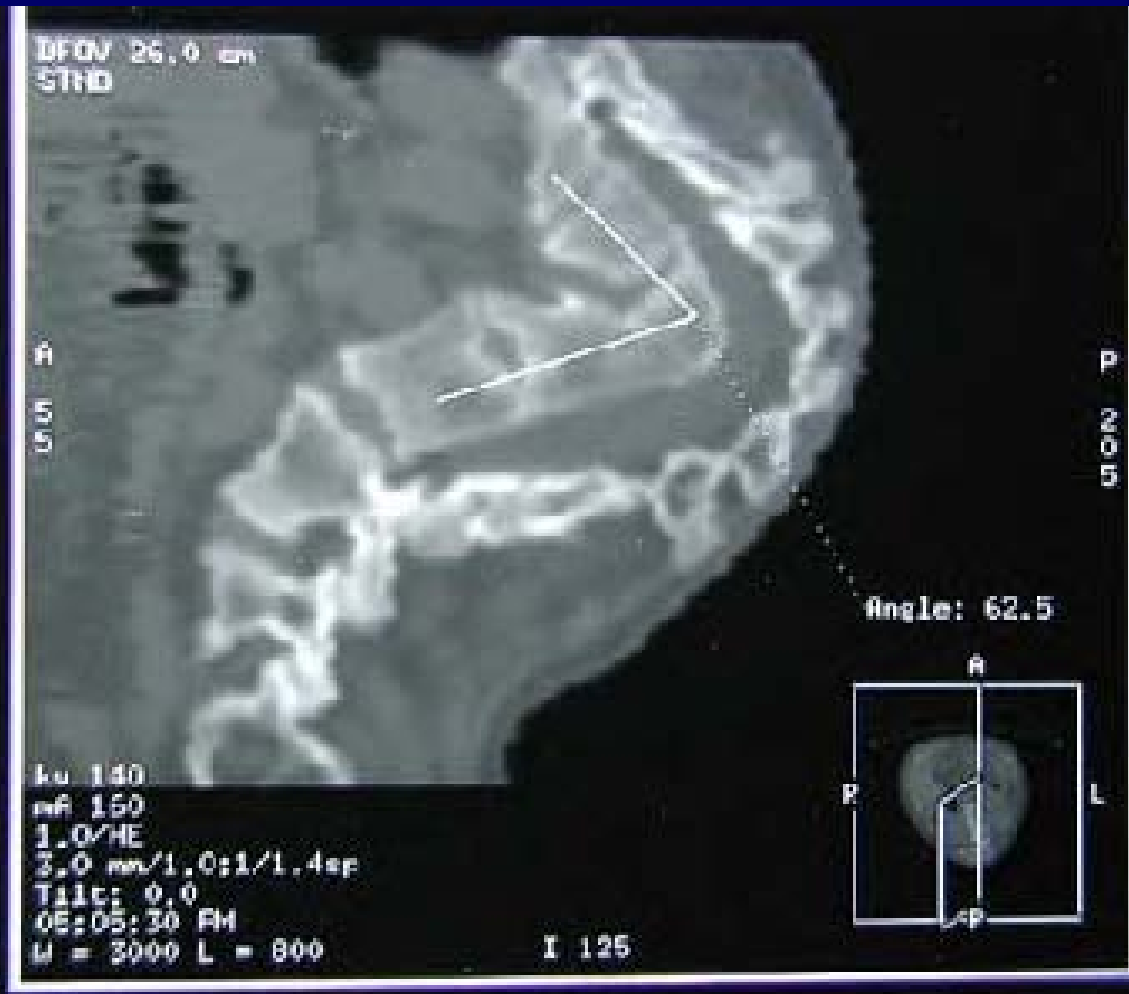OPERATIVE TREATMENT

- Surgical treatment of Scheuermann's kyphosis is also controversial
- Combined anterior and posterior
- Posterior
- Anterior

Scheuermann's Kyphosis – Differential Diagnosis

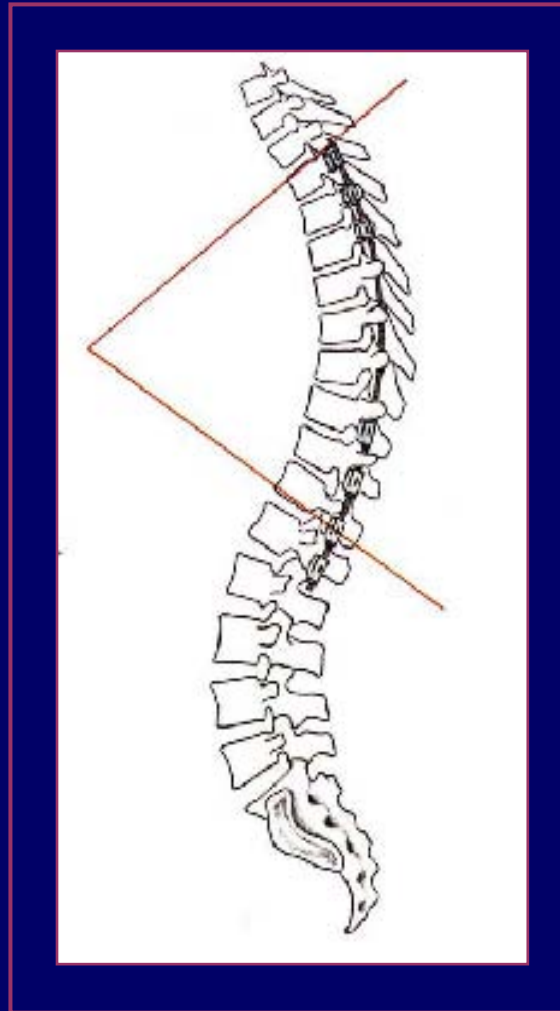
- Postural round back deformity is characterized by modest kyphosis (40° - 60°), is flexible and no radiologic changes
- Inflammation and infection may include discitis, osteomyelitis, and spondylitis (ankylosing spondylitis, Reiter's syndrome, psoriasis, and inflammatory bowel disease)
- Trauma due to multiple compression fractures
- tumors may include ABC, osteoid osteoma, osteoblastoma, EG, spinal cord tumors, and syringomyelia.
- Congenital kyphosis (type 2). See next slide.

Congenital Scoliosis

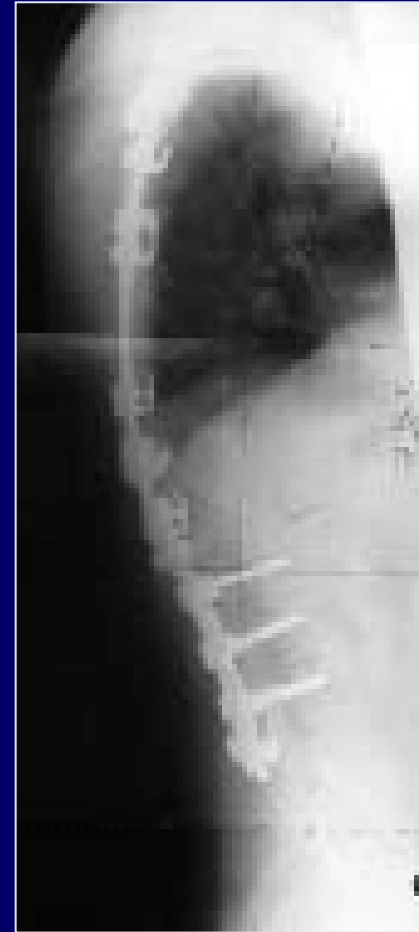
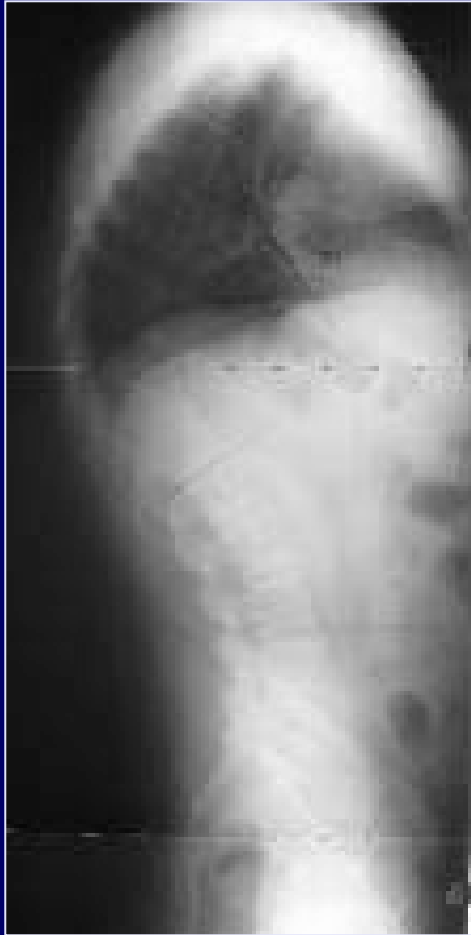
This is an example of Congenital Scoliosis. Abnormalities of the vertebral body can produce severe kyphotic deformities.

Operative Treatment of Scheuermann's Kyphosis



Operative Treatment of Scheuermann's Kyphosis



Segmental instrumentation and anterior thorascopic release. Segmental instrumentation corrects different large curves.

Scheuermann's Kyphosis – Surgical Indications

- “Severe deformity after growth completion with unremitting pain (usually $>65^\circ$ and $>10^\circ$ wedging and resistant to bracing for 6 months)”
- Neurologic signs or symptoms (rarely reported in literature, maybe related to thoracic disc herniation, epidural cysts, or the hyperkyphosis itself, and tend to occur in adult patients.
- Pain
- Progressive deformity
- neurologic compromise
- cardiopulmonary compromise (kyphosis $>100^\circ$)
- cosmesis

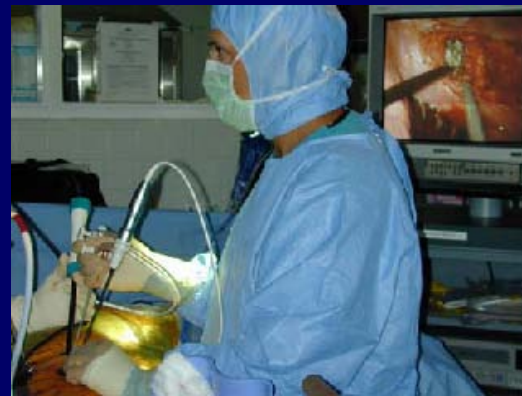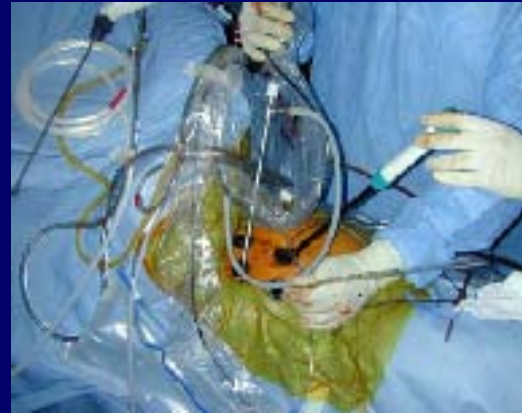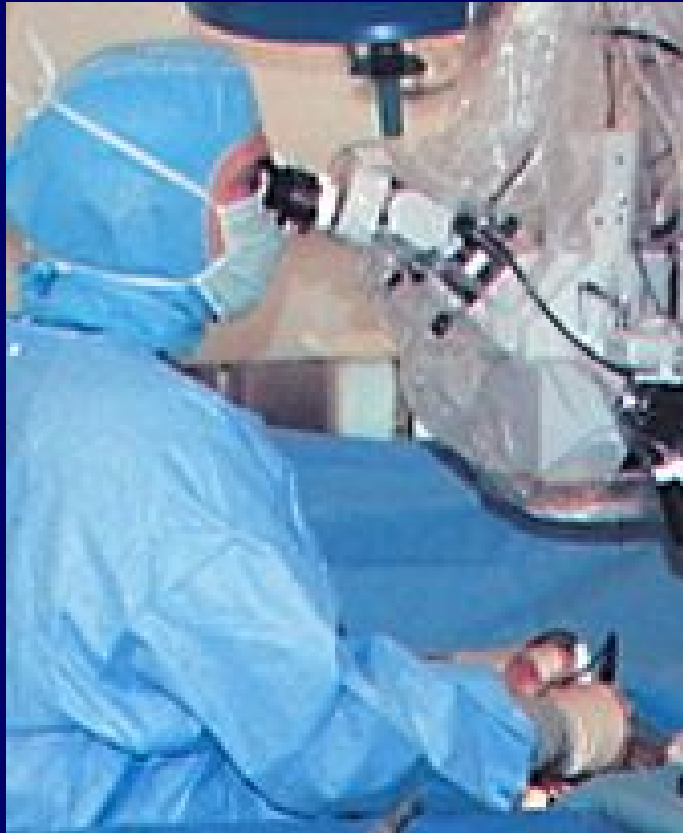Scheuermann's Kyphosis – Surgery Considerations

- Postoperative regimen : cast or TLSO for 6 to 9 months until solid fusion.
- Complications include pseudarthrosis and instrument failure (greater in posterior fusion alone), loss of correction, infection, pulmonary complications, and neurologic deficits.
- Expected postoperative correction is about 50%.

Scheuermann's Kyphosis – Surgery -Technique

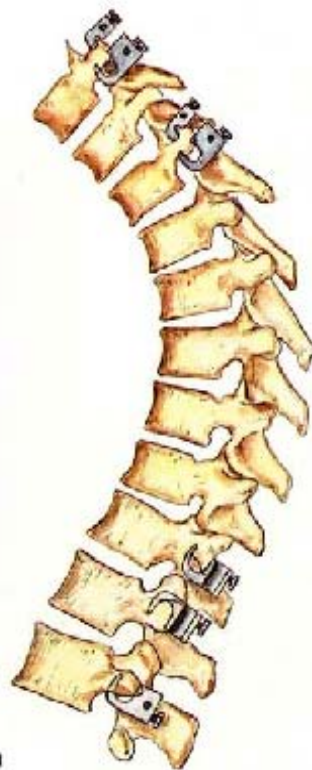- Posterior long fusion and instrumentation for curves $<65^\circ$ and bending correction to $< 50^\circ$.
 - Surgery - technique
 - Posterior instrumentation should extend the entire kyphotic region, and distally, it should include one lordotic vertebra (usually L1 or L2)
 - Instrumentation should be applied with gradual cantilever bending and segmental compression forces.
 - Multiple posterior osteotomies may improve correction.
 - Anterior fusion (transthoracic approach -open or thoracoscopic technique), followed by posterior fusion and instrumentation for curves $> 65^\circ$ with bending correction to still $> 50^\circ$.

Scheuermann's Kyphosis – Thorascopic Release



Scope and instruments are inserted through a small hole in the patient's chest. Dr. Pashman carefully removed each disc allowing the patient's spine to be loosened. In the middle picture, you can see Dr. Pashman viewing the spine as the discs are removed.

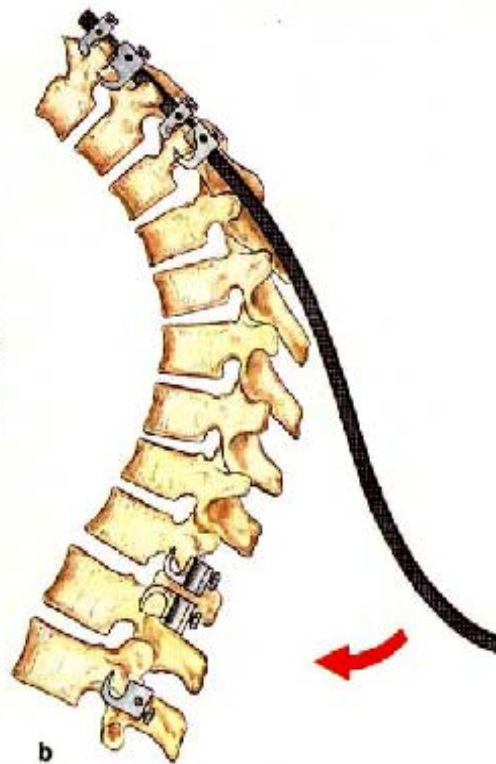Operative Treatment of Scheuermann's Kyphosis



a

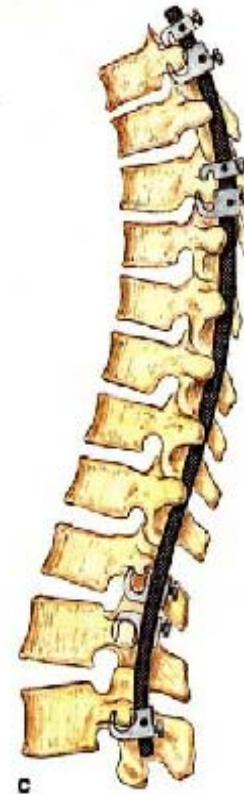Correction of kyphosis using the Cotrel–Dubousset system.

a Claw grip at the cranial and caudal ends of the curve. Note: opposite placement of the laminar hooks at L1 and L2 allows induction of lumbar lordosis.



b

b Correction of kyphosis with an appropriately bent Cotrel rod. Note: induction of lumbar lordosis by caudal bending of rod.



c

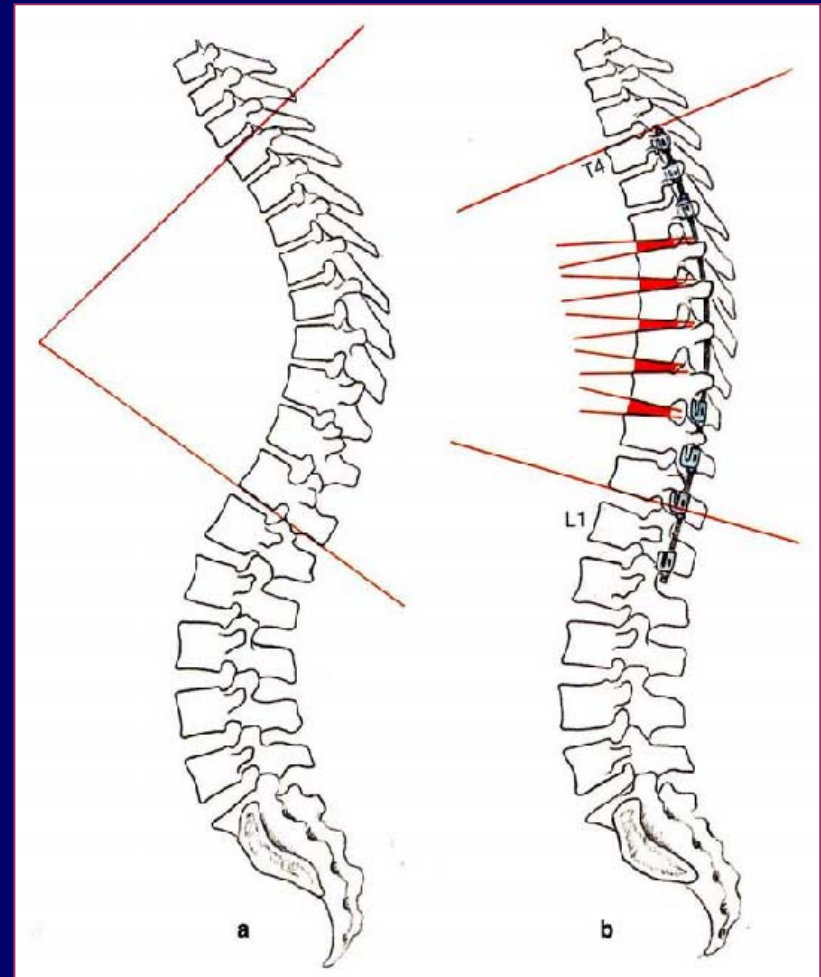
c, d Correct implant seating in both planes. Restoration of physiological curvatures. Stabilization with a DTT.



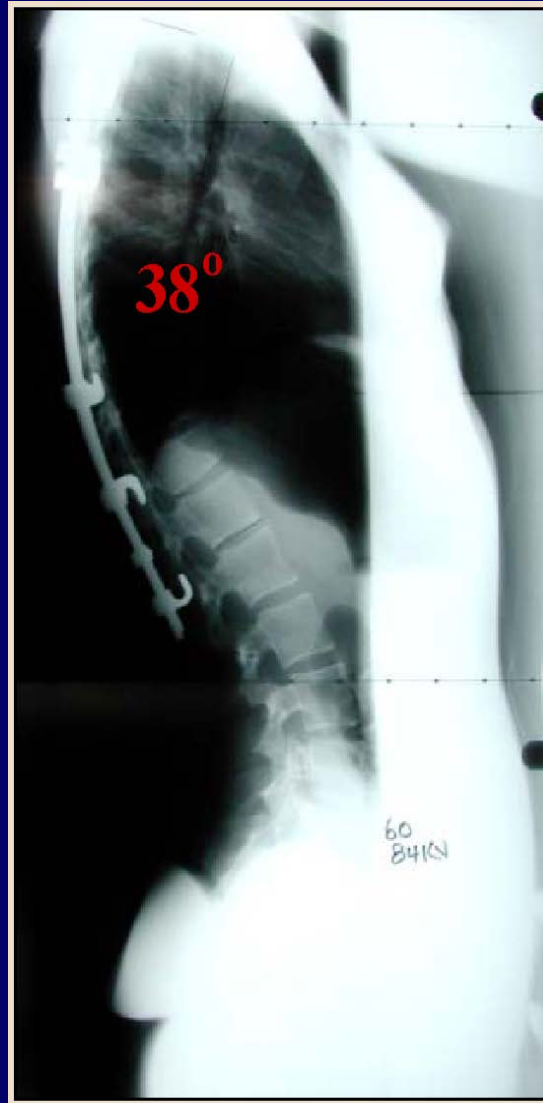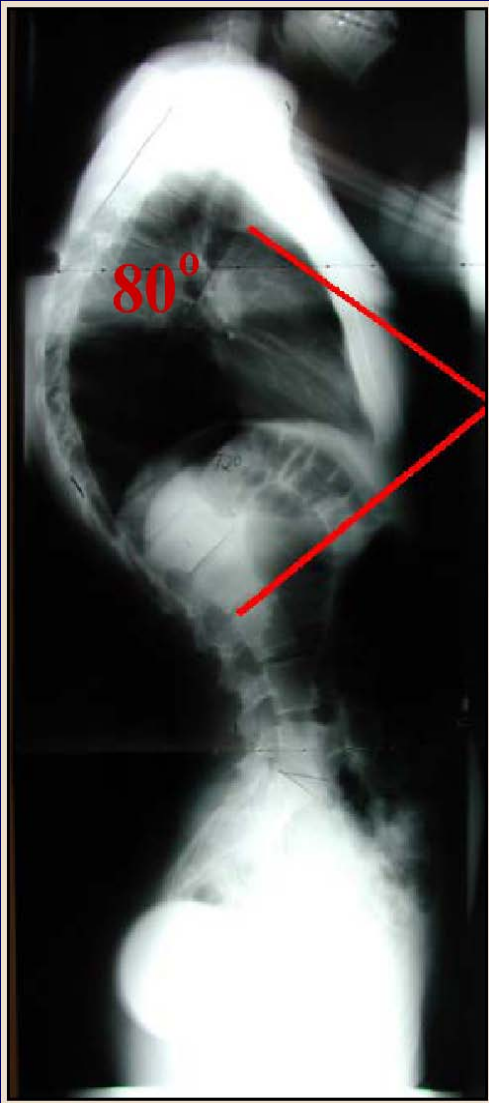d

Goals of Operative Treatment of Scheuermann's Kyphosis

- Posterior long rod multi-segment kyphosis correction
- +/- anterior release and interbody fusion



Surgical Fusion for Scheuermann's Kyphosis



Rigid curves over 75° not amenable to bracing will require surgery for cosmesis.

An anterior release with interbody fusion followed by a posterior fusion with instrumentation would be performed.

Compression forces are applied to the curve to reduce the angulation and a fusion is performed.

Classifications of Kyphosis - Congenital

1. Postural
2. Scheuermann's
3. Congenital
4. Neuromuscular
5. Myelomeningocele
6. Traumatic
7. Post-surgical
8. Post-irradiation
9. Metabolic
10. Skeletal dysplasias
11. Collagen disease
12. Tumor
13. Inflammatory

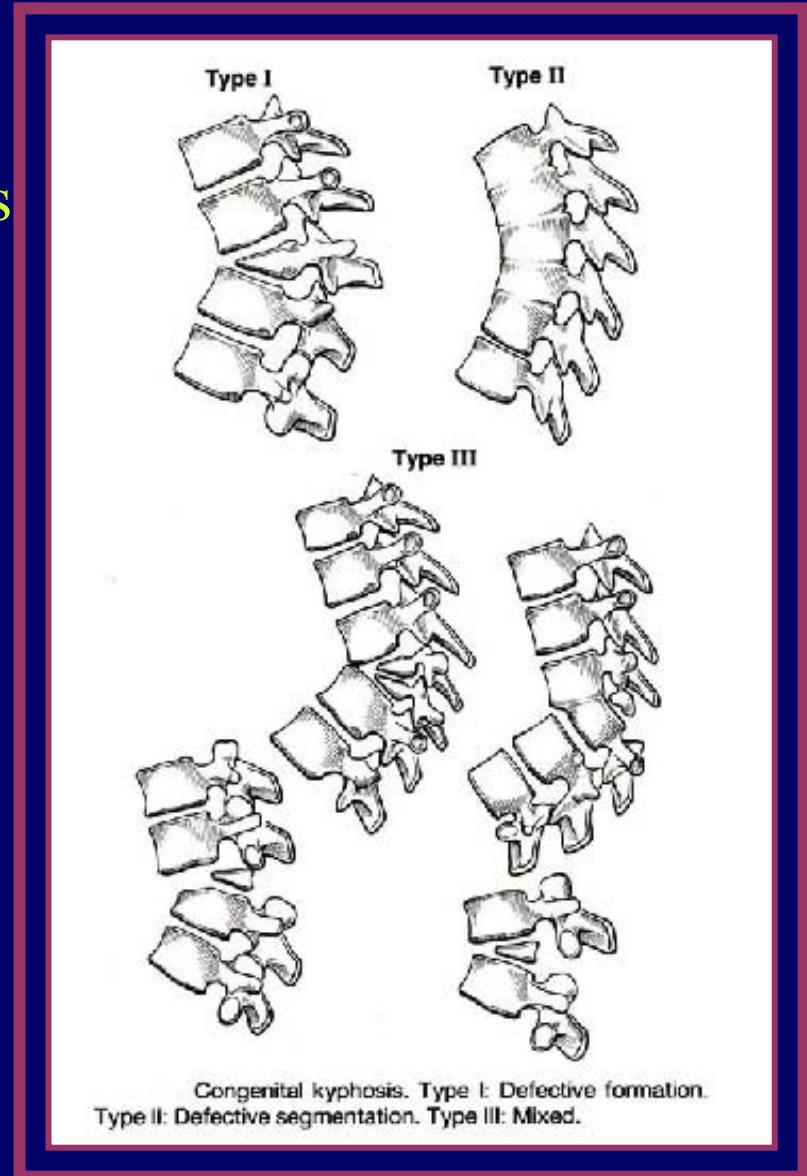
Congenital Kyphosis appears in infants where there is a defect in the vertebral formation causing two or more vertebra to fuse together forming a “bar”. This is a progressive disease, and left untreated, pulmonary failure and paralysis are imminent. Early surgical intervention is crucial.

An MRI is performed to check for infringement on the spinal cord. An Anterior/Posterior fusion with a staged anterior release, decompression of the spinal cord, fusion, and strut grafts.

Congenital Kyphosis

CLINICAL FINDINGS

- Various different vertebral anomalies
- Most common noninfectious, non-traumatic deformity to cause paraplegia
- Paralysis is most likely to occur during the years of spinal growth
- Treatment of resection of anomalous vertebra(e) and AP reconstruction



Classifications of Kyphosis – Neuromuscular

1. Postural
2. Scheuermann's
3. Congenital
4. Neuromuscular
5. Myelomeningocele
6. Traumatic
7. Post-surgical
8. Post-irradiation
9. Metabolic
10. Skeletal dysplasias
11. Collagen disease
12. Tumor
13. Inflammatory

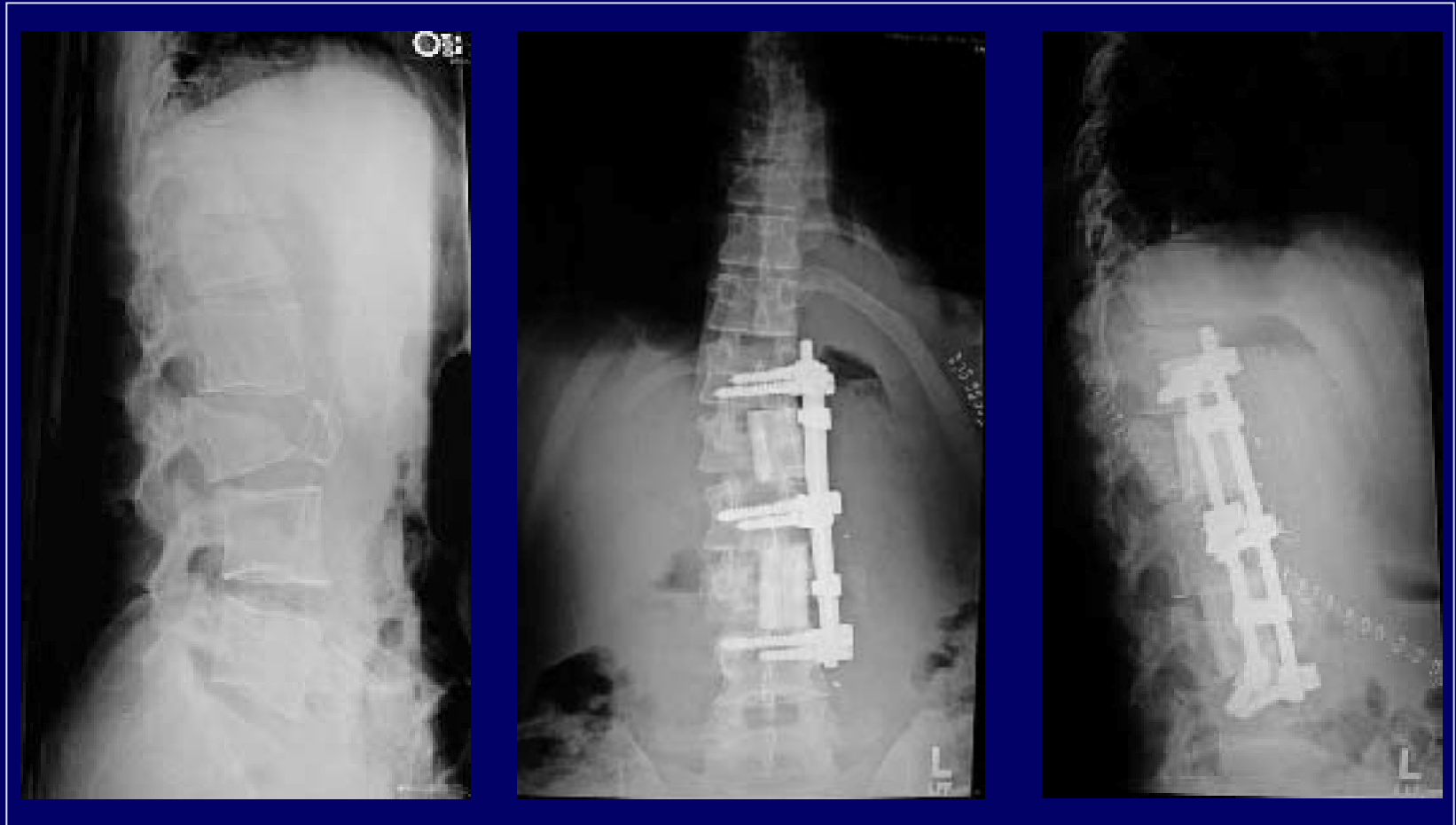
Neuromuscular Kyphosis is found in children with a disorder of the neuromuscular system, such as cerebral palsy, spinal bifid, and muscular dystrophy. It may also be found in children who have had a spinal cord injury. The child will have an extremely weak trunk. Surgery is performed to improve quality of life, for example to help a child sit up in their wheelchair.

Classifications of Kyphosis - Traumatic

1. Postural
2. Scheuermann's
3. Congenital
4. Neuromuscular
5. Myelomeningocele
6. Traumatic
7. Post-surgical
8. Post-irradiation
9. Metabolic
10. Skeletal dysplasias
11. Collagen disease
12. Tumor
13. Inflammatory

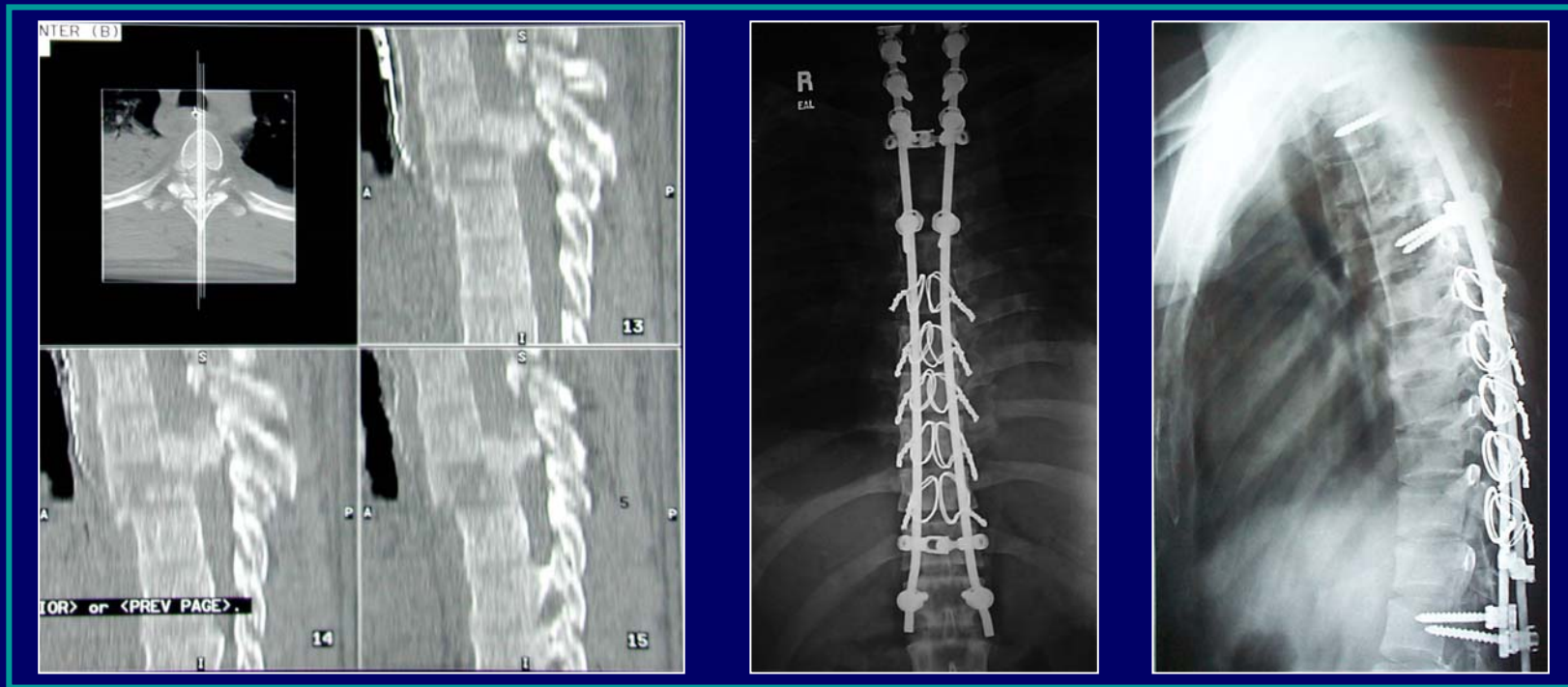
Traumatic Kyphosis is common from a burst fracture or a compression fracture. The kyphosis may result from the injury or as a surgical complication.

Traumatic Kyphosis Correction— Short Segment



Multiple level lumbar burst fracture procedure. Anterior fixation restores sagittal (lateral view) balance.

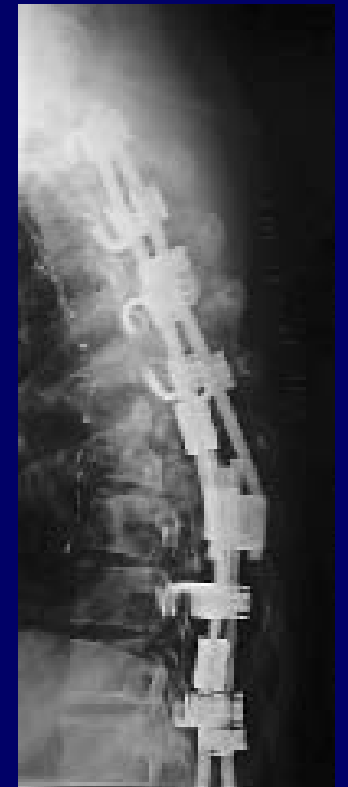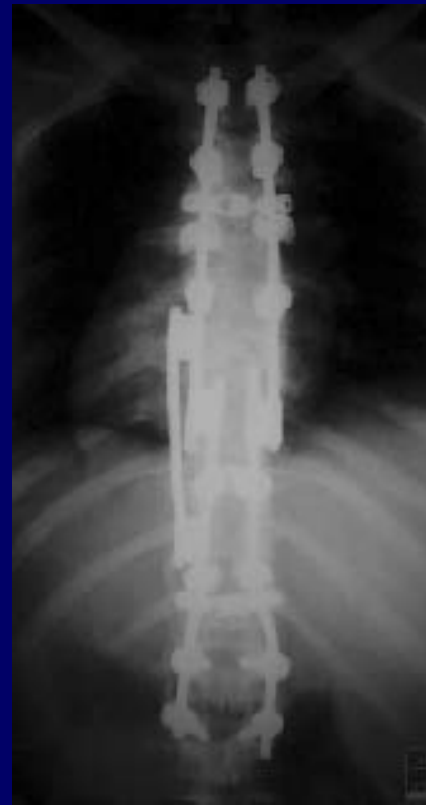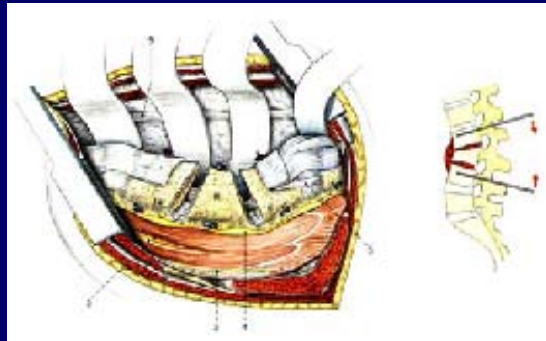
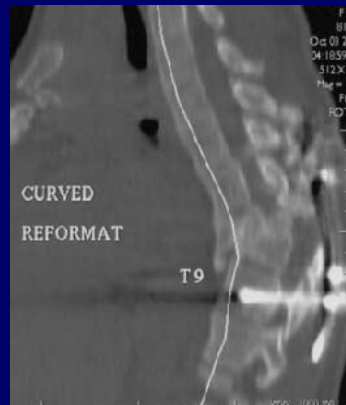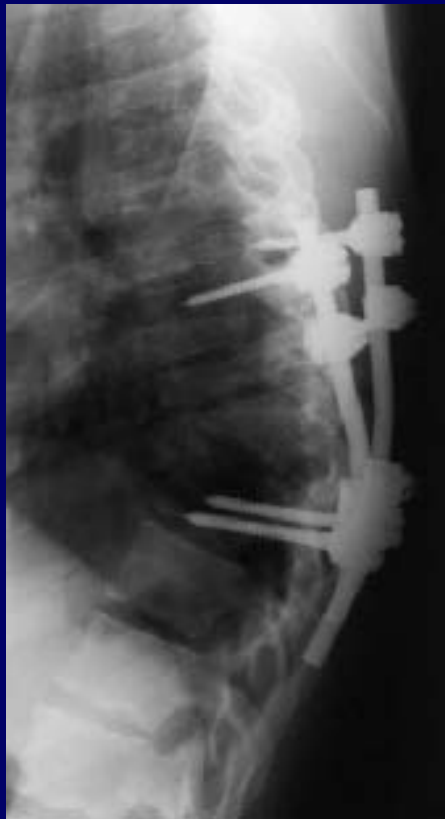
Traumatic Kyphosis Correction--Long Segment



Case example: 26 year old high speed MCA and T5 fracture subluxation, neurologically complete.

Surgery: posterior long segment (T1-L1) fusion

Traumatic Kyphosis Correction— Long Segment



Case example: 17 year old MVA and T9 fracture with complete neurologic injury. Failed posterior short segment fusion. Surgery: anterior osteotomy and posterior long segment